

Successful Treatment of Infertility Due to Anejaculation with In Vitro Fertilization and Embryo Transfer: A Report of Two Cases

SEIICHIRO NAGAI, TSUYOSHI KASAI, KEIGO OGAWA,
KAORUKO MIZUNO, SHOJI OHTA and KAZUHIKO HOSHI

*Department of Obstetrics and Gynecology, Yamanashi
Medical University, Yamanashi 409-3898*

NAGAI, S., KASAI, T., OGAWA, K., MIZUNO, K., OHTA, S. and HOSHI, K. *Successful Treatment of Infertility Due to Anejaculation with In Vitro Fertilization and Embryo Transfer: A Report of Two Cases.* Tohoku J. Exp. Med., 1998, 184 (3), 241-246 — We investigated the efficacy of assisted ejaculation in combination with in vitro fertilization and embryo transfer (IVF-ET) in two couples with infertility due to anejaculation. Case 1 was in an anejaculatory condition associated with a spinal cord-injury. We performed intrauterine insemination (IUI) three times using motile sperm obtained by intrathecal injection of neostigmine, but no pregnancy followed. The couple then entered IVF-ET. The semen volume obtained by assisted ejaculation was 4.5 ml. The sperm count was $33 \times 10^6/\text{ml}$ with 33% motility. At 35 weeks of gestation she delivered three healthy babies by cesarean section. Case 2 was in an unexplained retrograde ejaculatory condition. We performed IUI eight times before changing to IVF-ET. We then used sperm obtained from urine or sperm recovered from the bladder after administration of human tubal fluid, but no pregnancy followed. At the fifth IVF-ET attempt, using sperm obtained from urine, we succeeded. We prepared the sperm by the Percoll gradient method. The sperm count was $36 \times 10^6/\text{ml}$ with 64% motility. At 39 weeks of gestation she delivered a healthy baby. Deficient seminal quality contributes to the decreased fertility potential in patients with anejaculation. With the use of IVF-ET methods, pregnancies can be achieved in these couples. ————— male infertility; anejaculation; spinal cord injury; retrograde ejaculation; IVF-ET © 1998 Tohoku University Medical Press

Anejaculation is an uncommon cause of infertility that has been treated successfully with different artificial reproductive techniques, e.g., intrauterine insemination (IUI) (Linden et al. 1992; Ranieri et al. 1995), in vitro fertilization and embryo transfer (IVF-ET) (Hovatta and Smitten 1993; Dahlberg et al. 1995; Hultling et al. 1995), gamete intra-fallopian transfer, and intracytoplasmic sperm

Received October 23, 1997; revision accepted for publication January 28, 1998.

Address for reprints: Seiichiro Nagai, M.D., Department of Obstetrics and Gynecology, Yamanashi Medical University, Yamanashi 409-3898, Japan.

e-mail: seiichi@res.yamanashi-med.ac.jp

injection (ICSI) (Gerris et al. 1994; Hovatta et al. 1996). IUI requires a certain number of motile spermatozoa. But the sperm obtained from a man in an anejaculate condition tends to be lower in quality (Hirsch et al. 1992; Hen et al. 1995; Lamirande et al. 1995; Sedor and Hirsch 1995). We investigated the efficacy of assisted ejaculation in combination with IVF-ET in two couples with infertility due to anejaculation.

CASE REPORTS

Case 1

In 1989, a 32-year-old man was referred to our hospital because of infertility due to lack of ejaculation. He suffered thoracic 4 and under spinal cord damage because of a traffic accident at 28 years of age. Since then he has had an anejaculatory condition associated with a spinal cord injury (SCI). His wife was 25 years old and had regular menstrual cycles and proven ovulation. Patients with SCI who do not ejaculate spontaneously have been treated with vibratory stimulation (VS) or electroejaculation (EEJ) at many hospitals (Gerris et al. 1994; Dahlberg et al. 1995; Hultling et al. 1995; Hovatta et al. 1996). But because we did not have VS or EEJ systems, we adopted the method of intrathecal injection of neostigmine (Guttmann and Walsh 1970). After obtaining informed consent of the couple, we performed IUI three times using motile sperm obtained by intrathecal injection of neostigmine (wagostigumine; Shionogi, Osaka), but no pregnancy resulted from three efforts.

In August 1994, the couple entered our IVF-ET program (Nagai et al. 1997). In preparation for IVF treatment, his wife underwent a long gonadotropin-releasing hormone agonist, busereline acetate (Suprecure; Hoechst Japan, Tokyo) protocol and was then stimulated with human menopausal gonadotropin (Pergonal; Teikoku Hormone MFG, Tokyo). Oocyte retrieval was performed by transvaginal aspiration.

The progress after intrathecal injection of neostigmine is illustrated in Fig. 1. After lumbar puncture at L4/L5, 0.5 mg of neostigmine was injected. We monitored pulse and blood pressure during the procedure. At 3 hours after intrathecal injection, no ejaculation occurred. We injected 0.5 mg of neostigmine once more. An ejaculation was produced 4 hours after the second injection. Table 1 shows original and prepared semen characteristics. The semen volume obtained by assisted ejaculation was 4.5 ml. The sperm count was 33×10^6 /ml with 33% motility. Fig. 2 summarizes the procedures for preparing sperm. When we prepared semen by the Percoll gradient method, the sperm motility was increased from 33% to 86%. Five hours after oocyte retrieval, the oocytes were inseminated with 100 000 motile sperm per oocyte. After insemination of 12 oocytes, 6 oocytes became fertilized, and three 4-cell embryos were transferred. Living three fetuses were seen on the ultrasound scan by 7 weeks of gestation. At 35 weeks' gestation, she delivered three healthy babies by cesarean section.

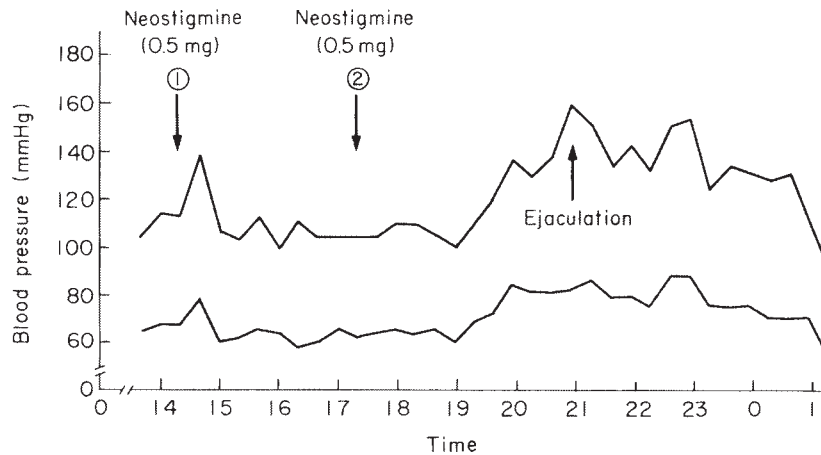


Fig. 1. Procedure. After lumbar puncture L4/L5, 0.5 mg of neostigmine was injected. We monitored the blood pressure during the procedure. At 3 hours after an initial intrathecal injection, no ejaculation had occurred. Ejaculation was produced 4 hours after the second injection.

TABLE 1. *Original and prepared semen characteristics*

Case 1	Original	After preparation
Volume (ml)	4.5	
Sperm conc. (10^6 /ml)	33.0	23.0
Motility (%)	33.3	86.4
Teratozoospermia (%)	21.2	0.0
WBC (10^6 /ml)	3.0	1.0
Viscosity	+	

Case 2

A 33-year-old man was referred to our hospital because of infertility due to incomplete ejaculation. He was diagnosed with retrograde ejaculation because of the presence of spermatozoa in his postmasturbatory urine. The semen volume of antegrade ejaculation ranged from 0 ml to 0.5 ml. His wife was 31 years old and had regular menstrual cycles and proven ovulation. We performed IUI eight times before changing to the IVF-ET program. We then used sperm obtained from urine or recovered from the bladder after administration of human tubal fluid (HTF; Gibco, Grand Island, NY, USA), but no pregnancy followed. The IVF-ET protocol was the same as in Case 1.

The fifth IVF-ET attempt using sperm immediately obtained from urine resulted in a successful impregnation. Fig. 3 shows the procedures for preparing sperm. We prepared sperm by the Percoll gradient method. Table 2 summarizes semen characteristics. The sperm motility was increased from 3% to 64%. After insemination of 5 oocytes, 3 oocytes were fertilized, and three 4-cell embryos

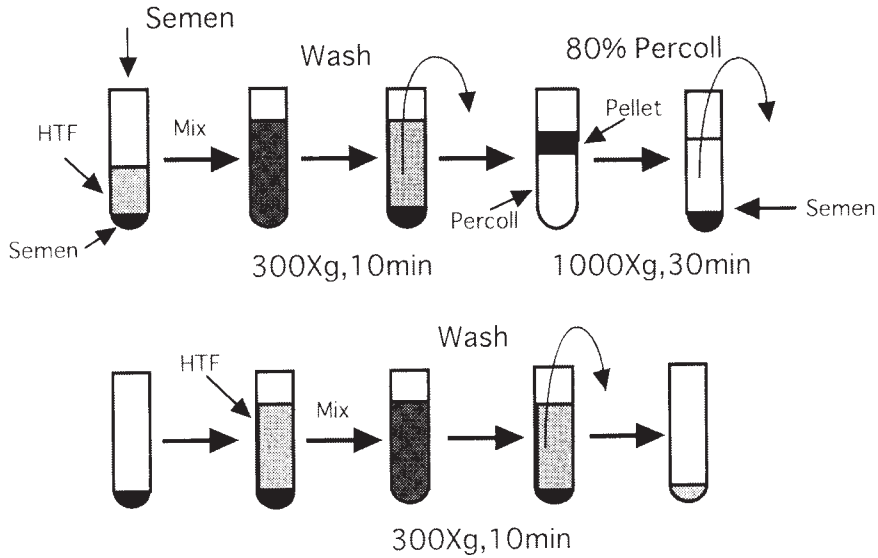


Fig. 2. Semen preparation: Case 1. The semen obtained by intrathecal injection of neostigmine was washed by human tubal fluid (HTF) at $300\times g$ for 10 minutes. The supernatant was removed and the remaining pellet loosened by HTF. The pellet was loaded onto the top of the 80% Percoll gradient and centrifuged at $1000\times g$ for 30 minutes. The supernatant was removed again and the pellet was washed by HTF (with 10% maternal semen). The sperm pellet was then resuspended in 0.5 ml of HTF for insemination.

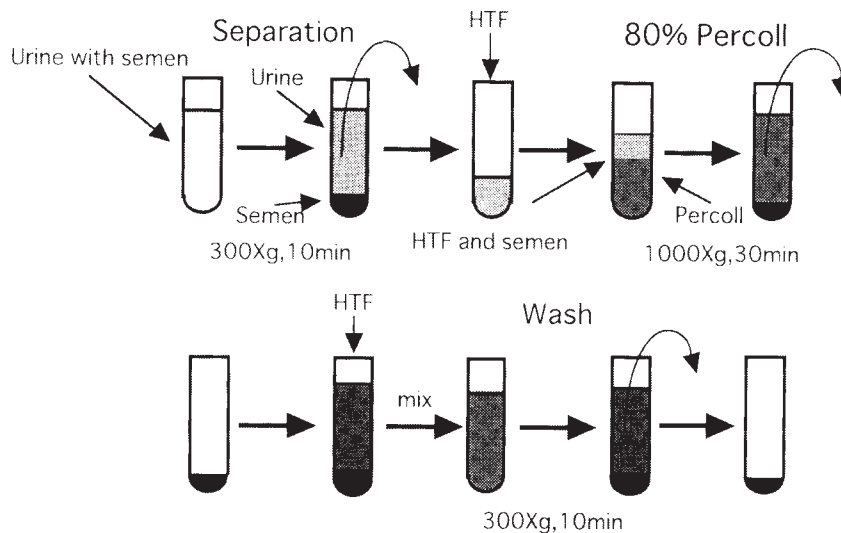


Fig. 3. Semen preparation: Case 2. After masturbation, the patient voided urine into a sterile container. Urine with semen was centrifuged at $300\times g$ for 10 minutes. The supernatant was removed and the remaining pellet loosened by HTF. The pellet was loaded onto the top of the 80% Percoll gradient and centrifuged at $1000\times g$ for 30 minutes. The supernatant was removed again and the pellet was washed by HTF (with 10% maternal serum). The sperm pellet was then resuspended in 0.5 ml of HTF for insemination.

TABLE 2. *Retrograde ejaculated and prepared semen characteristics*

Case 2	Retrograde ejaculated semen	After preparation
Sperm conc. (10^6 /ml)	88.0	36.0
Motility (%)	3.4	63.9
Teratozoospermia (%)	11.4	5.6
WBC (10^6 /ml)	0	0

retrograde ejaculated sperm (in bladder)

were transferred. At 39 weeks' gestation she delivered a healthy baby.

DISCUSSION

In general, infertility caused by an anejaculatory condition associated with a SCI has been treated by VS or EEJ (Gerris et al. 1994; Dahlberg et al. 1995; Hultling et al. 1995; Hovatta et al. 1996). If persistent anejaculation can not be overcome by VS or EEJ, spermatozoa obtained from the vas deferens (Hovatta and Smitten 1993; Dahlberg et al. 1995) or the epididymis during aspiration is used. However, because the sperm obtained by assisted ejaculation is usually poor in quality (Sedor and Hirsch 1995), the pregnancy rate after IUI is disappointingly low, 0%, 2.5% and less than 8% (Kaneko and Miyazaki 1993; Sedor and Hirsch 1995; Yamamoto et al. 1997). In vitro fertilization and embryo transfer or ICSI are thus utilized to treat infertility caused by anejaculation (Hovatta and Smitten 1993; Dahlberg et al. 1995). We obtained motile sperm by intrathecal injection of neostigmine according to the method reported by Guttman (Guttman and Walsh 1970). We performed intrathecal injection of neostigmine four times without an experience of severe side effects.

Retrograde ejaculation is a type of infertility that has also been treated successfully with various kinds of artificial reproduction technique such as IUI and IVF-ET (Hultling et al. 1995; Linden et al. 1995; Ranieri et al. 1995). All of these techniques require a minimal number of motile spermatozoa. When antegrade ejaculation cannot be restored pharmacologically, artificial reproduction is effected using the sperm recovered from urine, vas deferens, or epididymis. Because of urine pH and osmolarity, spermatozoa recovered from the bladder are rarely able to fertilize (Hen et al. 1995; Linden et al. 1995; Ranieri et al. 1995). In some cases, few spermatozoa with poor or no motility are found in urine voided immediately after masturbation. ICSI is indicated in such cases (Gerris et al. 1994). In the present case, because the spermatozoon obtained from urine was asthenozoospermia, we performed IUI eight times and IVF-ET four times.

Despite the limitations of reporting on two cases, our results are encouraging and suggest that assisted ejaculation in combination with IVF-ET may be the

treatment of choice in patients of male anejaculatory infertility. The sperm obtained from a man in an anejaculate condition is inferior in quality, and assisted ejaculation is very difficult. We recommend IVF-ET, when IUI or other treatments failed.

References

- 1) Dahlberg, A., Ruutu, M. & Hovatta, O. (1995) Pregnancy results from a vibrator application, electroejaculation, and a vas aspiration programme in spinal-cord injured men. *Hum. Reprod.*, **10**, 2305-2307.
- 2) Gerris, J., Royen, E.V., Mangel-Schots, K., Joostens, M. & Vits, A. (1994) Pregnancy after intracytoplasmic sperm injection of metaphase II oocytes with spermatozoa from a man with complete retrograde ejaculation. *Hum. Reprod.*, **9**, 1293-1296.
- 3) Guttmann, S.L. & Walsh, J.J. (1970) Prostagmin assessment test of fertility in spinal man. *Paraplegia*, **9**, 39-51.
- 4) Hen, D., Scabby, M.J. & Jeyendran, R.S. (1995) Effect of urine on the functional quality of human spermatozoa. *Fertil. Steril.*, **64**, 1216-1217.
- 5) Hirsch, I., Sedor, J., Caliahan, H. & Staas, W.E. (1992) Antispermantibodies in seminal plasma of spinal cord-injured men. *Fertil. Steril.*, **39**, 243-247.
- 6) Hovatta, O. & Smitten, K. (1993) Sperm aspiration from vas deferens and in-vitro fertilization in cases of non-treatable anejaculation. *Hum. Reprod.*, **8**, 1689-1691.
- 7) Hovatta, O., Reima, I., Foudila, T., Butzow, T., Johansson, K. & Smitten, K. (1996) Vas deferens aspiration and intracytoplasmic injection of frozen-thawed spermatozoa in a case of anejaculation in a diabetic man. *Hum. Reprod.*, **11**, 334-335.
- 8) Hultling, C., Rosenlund, B., Tornblom, M., Sjoblom, P., Garoff, L., Nyman, C. & Hillensjo, T. (1995) Transrectal electroejaculation in combination with in-vitro fertilization: An effective treatment of anejaculation infertility after testicular cancer. *Hum. Reprod.*, **10**, 847-850.
- 9) Kaneko, R. & Miyazaki, K. (1993) Study on semen collection from patients with anejaculation by electrostimulation. *Jpn. J. Urol.*, **84**, 1479-1488. (in Japanese with English abstract)
- 10) Lamirande, E., Hassouna, M., Leduc, B.E., Gagnon, C. & Iwasaki, A. (1995) Increased reactive oxygen species formation in semen of patients with spinal cord injury. *Fertil. Steril.*, **63**, 637-642.
- 11) Linden, P.J.Q., Nan, P.M., Velde, E.R. & Kooy, R.J. (1992) Retrograde ejaculation: Successful treatment with artificial insemination. *Obstet. Gynecol.*, **79**, 126-128.
- 12) Nagai, S., Yasumizu, T., Kasai, T., Hirata, S., Mizuno, K. & Kato, J. (1997) Effect of oocyte retrieval from a small leading follicle in the fixed schedule of the in vitro fertilization program. *J. Obstet. Gynaecol.*, **23**, 165-169.
- 13) Ranieri, D.M., Cormino, L., Simonetti, S., Selvaggi, L. & Vicino, M. (1995) Successful establishment of pregnancy by superovulation and intrauterine insemination with sperm recovered by a modified Hotchkiss procedure from a patient with retrograde ejaculation. *Fertil. Steril.*, **64**, 1039-1042.
- 14) Sedor, J.F. & Hirsch, I.H. (1995) Evaluation of sperm morphology of electroejaculates of spinal cord-injured men by strict criteria. *Fertil. Steril.*, **63**, 1125-1127.
- 15) Yamamoto, M., Yamada, K., Hirata, N., Hirayama, A., Kashiwai, H., Momose, H., Suemori, T., Shiomi, T., Hirao, Y. & Okajima, E. (1997) Electroejaculation and assisted reproductive techniques in the patients with spinal cord injury. *Jpn. J. Urol.*, **88**, 420-426. (in Japanese with English abstract)