

## Infantile Pulmonary Alveolar Proteinosis with Interstitial Pneumonia: Bilateral Simultaneous Lung Lavage Utilizing Extracorporeal Membrane Oxygenation and Steroid Therapy

TADAHIKO ITO, MASAMITSU SATO,<sup>1</sup> TADASHI OKUBO,<sup>2</sup> IWAO ONO<sup>3</sup> and JINZO AKABANE

*Department of Pediatrics,* <sup>1</sup>*Department of Anesthesiology,* <sup>2</sup>*Department of Cardiovascular Surgery,* <sup>3</sup>*Department of Pathology, Nakadohri General Hospital, Akita 010-8577*

ITO, T., SATO, M., OKUBO, T., ONO, I. and AKABANE, J. *Infantile Pulmonary Alveolar Proteinosis with Interstitial Pneumonia: Bilateral Simultaneous Lung Lavage Utilizing Extracorporeal Membrane Oxygenation and Steroid Therapy.* Tohoku J. Exp. Med., 1999, 187 (3), 279-283 — An infant with refractory pulmonary alveolar proteinosis (PAP) associated with severe interstitial pneumonia is described. Although she was treated by bilateral simultaneous lung lavage utilizing extracorporeal membrane oxygenation and steroid therapy, she died of progressive respiratory failure 28 days after admission. Histologic examination of lung autopsy specimen showed only partial alveolar spaces to be filled with a dense PAS positive granular eosinophilic material and showed severe interstitial pneumonia with marked fibrosis of alveolar walls and interstitium. The lung lavage seemed to be effective for PAP because the effluent fluid sufficiently became clear and the PAS positive material was detected only in partial alveoli. The full venoarterial cardiopulmonary bypass with extracorporeal membrane oxygenation seemed to be very useful to support bilateral lung lavage for small infants. The refractory symptoms and failure of treatment were resulted from the association of severe interstitial pneumonia. In neonates or infants with PAP and severe interstitial pneumonia with poor response for steroid therapy, the lung transplantation should be considered. ————— pulmonary alveolar proteinosis; interstitial pneumonia; lung lavage; extracorporeal membrane oxygenation © 1999 Tohoku University Medical Press

Pulmonary alveolar proteinosis (PAP) is rare disease, particularly in infants and children, and is of unknown etiology. We report an infant with refractory PAP associated with severe interstitial pneumonia.

---

Received February 16, 1999; revision accepted for publication February 26, 1999.

Address for reprints: Tadahiko Ito, M.D., Department of Pediatrics, Nakadohri General Hospital, 3-15 Misono-cho, Minami-dori, Akita 010-8577, Japan.

## CASE REPORT

The female infant with no relevant family history was born at 40 weeks' gestation weighing 3.3 kg. As mild cyanosis at 1 month of age, she was consulted to a nearby hospital. Chest x-ray revealed trivial abnormal shadowing on bilateral lung fields. Congenital heart diseases were ruled out because of normal echocardiographical findings. Thereafter, cyanosis at lips and nails gradually worsened with initiation of vomiting. She was admitted to our hospital at 1 year and 1 month of age because of failure to thrive. At the time of hospital admission, she was noted to be extremely thin, weighing only 7.3 kg ( $-2$  s.d.). Marked cyanosis at lips and nails and clubbing fingers were noted with tachypnea (50 per minute) and tachycardia (150 bpm). Chest x-ray revealed bilateral reticulonodular shadowing (Fig. 1). Blood examinations showed a mild leukocytosis ( $16\,890/\text{mm}^3$ ), polycythemia (hematocrit 48%, hemoglobin 15.4 g/100 ml), and elevation of serum-lactate dehydrogenase level (1126 IU/liter). Arterial blood gas analysis revealed marked hypoxemia (partial pressure of oxygen 35 mmHg, oxygen saturation 67%), and normal partial pressure of carbon dioxide. Because severe cyanosis and tachypnea were noted, 30% oxygen was administered. However, rapid deterioration of respiration and general condition necessitated ventilator support.

She was diagnosed as having interstitial pneumonia from the clinical symp-

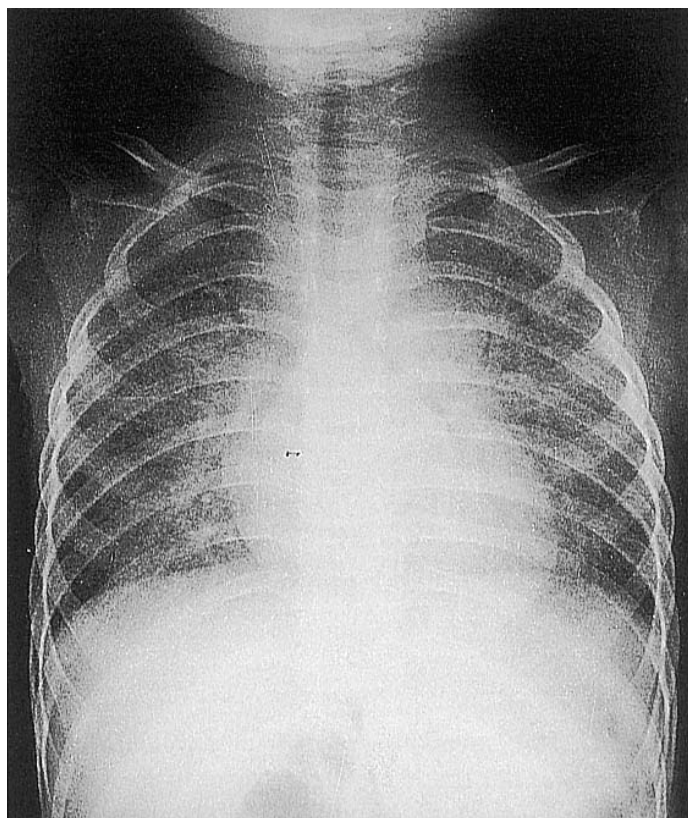


Fig. 1. Chest x-ray at admission revealed bilateral reticulonodular shadowing.

toms and findings of chest x-ray. Prednisolone therapy, 20 mg (1 mg/kg) daily, was started with a little response, and hypoxemia gradually deteriorated. Her sputum and effluent fluid of bronchopulmonary lavage were creamy and amorphous material positive to periodic acid-Schiff staining was detected in those samples, consistent with a diagnosis of PAP. The steroid therapy resulted in a slight improvement in hypoxemia and the oxygen tension of artery was 40 mmHg with 100% oxygen administration. On the 11th day after admission, bilateral simultaneous lung lavage utilizing extracorporeal membrane oxygenation (ECMO) with partial cardiopulmonary support using 14F double-lumen catheter cannulating the right internal jugular vein was performed. Pulmonary lavage was carried out with warmed (37°C) saline solution (total 1000 ml). Desaturation appearing during the lung filling with saline solution required intermittent bagging. The first lung lavage transiently improved the hypoxemia and the oxygen tension of artery was 206 mmHg with 70% oxygen. However, 100% oxygen was required on the following day.

On the 18th day after admission, the second lung lavage on full venoarterial cardiopulmonary bypass with ECMO was performed. The right internal jugular vein and right internal jugular artery were used for cannulation. Sufficient lung lavage with mechanical chest percussion and postural drainage could be carried out without desaturation during the filling of lung with saline solution. Twenty lavage cycles were carried out with a total volume of lavage fluid of 3700 ml and the effluent was sufficiently clear. A postlavage chest radiograph showed an improvement of lung shadowing and inspired oxygen concentration could be weaned from 100% to 50% the following day. However, respiratory distress gradually worsened thereafter, and she died in spite of continuity of steroid therapy 28 days after admission.

Post mortem examination was performed. Histologic examination of lung autopsy specimen showed only partial alveolar spaces to be filled with a dense PAS positive granular eosinophilic material (Fig. 2). In addition, lung autopsy specimen showed also severe interstitial pneumonia with marked fibrosis of alveolar walls and interstitium (Fig. 3).

#### DISCUSSION

Lung lavage is a well-recognized method of treatment for PAP. ECMO has been used to support total gas exchange during lung lavage for children PAP (Hiratzka et al. 1983; Hurrion et al. 1994; Mahut et al. 1996). But previous reports demonstrated the severe clinical features and poor prognosis in congenital and infant PAP (Colon et al. 1971; Hiratzka et al. 1983; Moulton et al. 1992; Mahut et al. 1996). In our case, the lung lavage utilizing ECMO resulted in transient and partial remission. The lung lavage seemed to be effective for PAP because the effluent fluid sufficiently became clear and the PAS positive material was detected only in partial alveoli. The full venoarterial cardiopulmonary

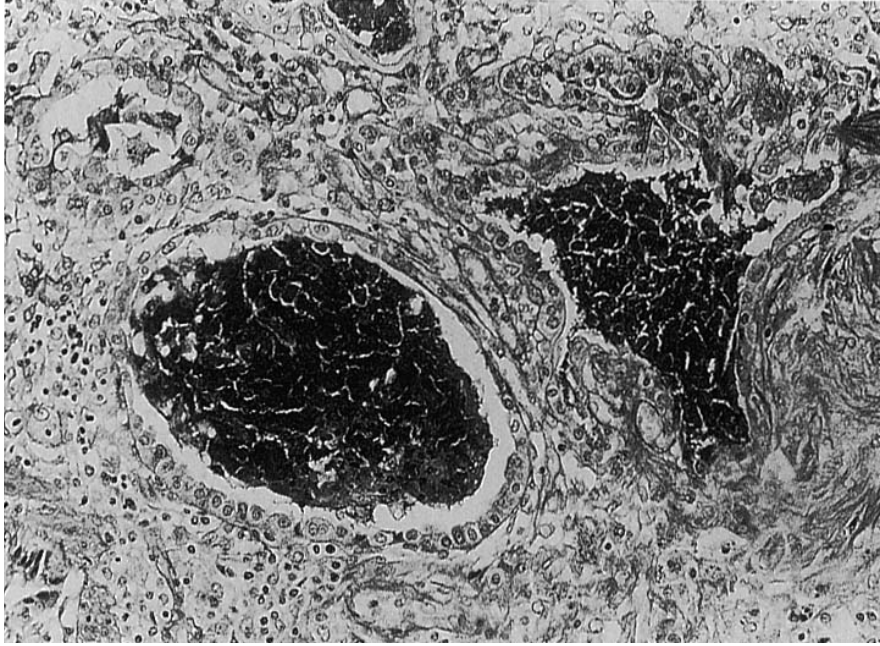


Fig. 2. Lung autopsy specimen shows completely filled alveoli containing the periodic acid-Schiff-staining amorphous material.

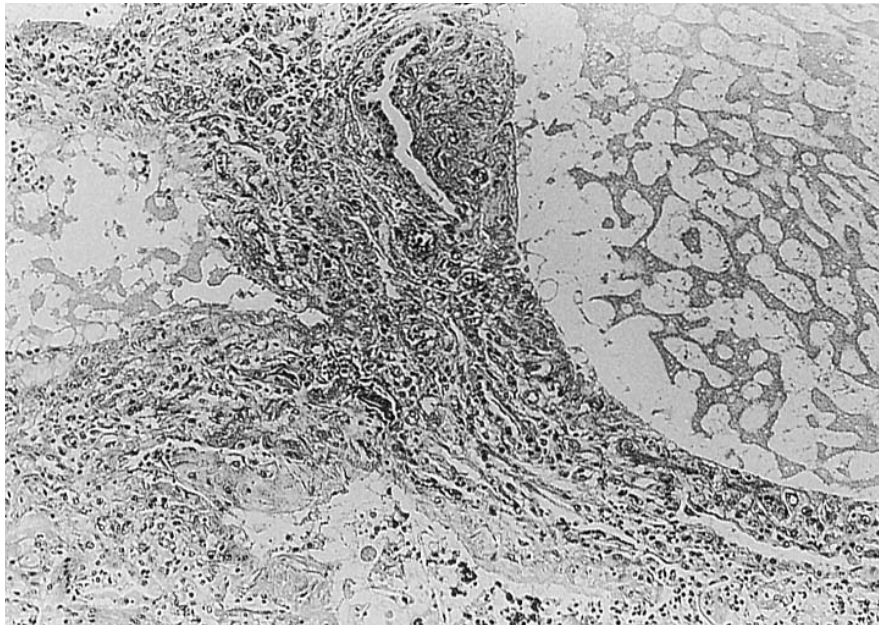


Fig. 3. Lung autopsy specimen shows interstitial pneumonia with marked fibrosis of alveolar walls and interstitium (hematoxylin-eosin staining).

bypass with ECMO seemed to be very useful to support bilateral lung lavage for small infants. The refractory symptoms and failure of treatment in our case were resulted from the association of severe interstitial pneumonia. Hiratzka et al. (1983), reported an infant with PAP and interstitial pneumonia and indicated the effect of steroid therapy on this disease. However, in our case, interstitial pneumonia could not be improved by steroid therapy. Pathogenesis in neonate and infant PAP showing severe clinical features would be different from that in

adult and childhood PAP showing natural remission or remission by lung lavage. We think that the difference in the pathogenesis may consist with the difference in the degree of complicating interstitial pneumonia. Therefore, in severe neonate or infant PAP, lung biopsy should be performed not only to make diagnosis of PAP but also to estimate the existence and degree of interstitial pneumonia for planning of therapy. In patients with severe interstitial pneumonia, steroid therapy should be preceded before lung lavage because improvement by only lung lavage would not be expected like our case. Only the patient showing the remission of interstitial pneumonia by steroid therapy has indication for lung lavage utilizing ECMO. In neonates or infants with PAP and severe interstitial pneumonia with poor response for steroid therapy, the lung transplantation should be considered (Bellon et al. 1992).

#### References

- 1) Bellon, G., Ninet, J., Louis, D., Jocteur Monrozier, D. & Champsaur, G. (1992) Heart-lung transplantation in a 16-month-old infant. *Chest*, **102**, 299-300.
  - 2) Colon, A.R., Jr., Lawrence, R.D., Mills, S.D. & O'Connell, E.J. (1971) Childhood pulmonary alveolar proteinosis (PAP). *Am. J. Dis. Child.*, **121**, 481-485.
  - 3) Hiratzka, L.F., Swan, D.M., Rose, E.F. & Ahrens, R.C. (1983) Bilateral simultaneous lung lavage utilizing membrane oxygenator for pulmonary alveolar proteinosis in an 8-month-old infant. *Ann. Thorac. Surg.*, **35**, 313-317.
  - 4) Hurrion, E.M., Pearson, G.A. & Firmin, R.K. (1994) Childhood pulmonary alveolar proteinosis. Extracorporeal membrane oxygenation with total cardiopulmonary support during bronchopulmonary lavage. *Chest*, **106**, 638-640.
  - 5) Mahut, B., Delacourt, C., Scheinmann, P., de Blic, J., Mani, T.M., Fournet, J.C. & Bellon, G. (1996) Pulmonary alveolar proteinosis: Experience with eight pediatric cases and a review. *Pediatrics.*, **97**(1), 117-122.
  - 6) Moulton, S.L., Krous, H.F., Merritt, T.A., Odell, R.M., Gangitano, E. & Cornish, J.D. (1992) Congenital pulmonary alveolar proteinosis: Failure of treatment with extracorporeal life support. *J. Pediatr.*, **120**, 297-302.
-