

Acute Glomerulonephritis Superimposed on Focal Segmental Glomerulosclerosis: A Case Report

HIROSHI TANAKA, SHINOBU WAGA, TOHRU NAKAHATA, NAOHIRO KONDO,¹ NORIO ONODERA¹ and NOBUHIRO MONMA²

Department of Pediatrics, Hirosaki University School of Medicine, Hirosaki 036-8562, ¹Division of Pediatrics, Iwate Prefectural Kitakami Hospital, Kitakami 024-0063, and ²Division of Pathology, Morioka Red Cross Hospital, Morioka 020-8560

TANAKA, H., WAGA, S., NAKAHATA, T., KONDO, N., ONODERA, N. and MONMA, N. *Acute Glomerulonephritis Superimposed on Focal Segmental Glomerulosclerosis: A Case Report.* Tohoku J. Exp. Med., 2000, **191** (3), 177-181 — A 9-year-old boy was referred to our hospital because of significant hematuria and proteinuria associated with hypocomplementemia. Although he had had a 3-year history of asymptomatic persistent proteinuria detected by urine screening of school children, he did not visit a physician. Finally, he visited a regional hospital, and hypocomplementemia was noted there. A percutaneous renal biopsy performed hospital day 4 revealed diffuse endocapillary proliferative glomerulonephritis with severe tubulointerstitial changes. Although his hematuria and hypocomplementemia spontaneously subsided within a month, proteinuria remained. A renal biopsy performed 4 months after the first renal biopsy revealed the lesion suggesting advanced focal segmental glomerulosclerosis (FSGS). Despite corticosteroid treatment, his proteinuria persisted, and he developed end stage renal failure. These clinical observation indicated that he had acute glomerulonephritis (AGN) superimposed on non-nephrotic FSGS, and that the episode of AGN might cause exacerbation of the FSGS. ——— acute glomerulonephritis; exacerbation; focal segmental glomerulosclerosis; superimposed nephritis © 2000 Tohoku University Medical Press

Primary focal segmental glomerulosclerosis (FSGS) without nephrotic syndrome (NS) of childhood in Japan is often found at urine mass screening of school children, as an asymptomatic constant isolated proteinuria (Yoshikawa et al. 1991). Hence, several chronic glomerulonephritis (CGN) associated with unfavorable

Received May 25, 2000; revision accepted for publication July 4, 2000.

Address for reprints: Hiroshi Tanaka, M.D., Department of Pediatrics Hirosaki University School of Medicine, 5 Zaifu-cho, Hirosaki 036-8562, Japan.

e-mail: hirotana@cc.hirosaki-u.ac.jp

outcome such as FSGS in Japan could be detected by chance. While, postinfectious acute glomerulonephritis (AGN), such as poststreptococcal AGN: the short-term and long-term prognoses are known to be favorable (Clark et al. 1988), sometimes occurs in the proportion of patient with CGN (Bertani et al. 1986; Kamiya et al. 1991; Kubo et al. 1994; Scully et al. 1995). So far it has been reported that several glomerulonephritis superimposed on the each other (Bertani et al. 1986; Gallego et al. 1991). However, to our knowledge, there is no published report to describe AGN superimposed on FSGS.

We encountered a Japanese boy aged 9 years with a 3-year history of asymptomatic persistent proteinuria detected by urine mass screening of school children, and who developed transient hematuria and hypocomplementemia. His clinical course and repeated renal biopsy findings suggested that he had an AGN superimposed on FSGS without NS. His renal function progressively deteriorated after the episode of AGN.

CASE REPORT

A 9-year-old well developed boy was referred to our hospital because of non-nephrotic range proteinuria, microscopic hematuria and hypocomplementemia. Although he had a 3-year history of proteinuria detected at urine mass screening of school children, he did not visit a physician since he had had no complaint. At the age of 9 years, he finally visited a municipal hospital, with complaint of proteinuria with hematuria, and hypocomplementemia (C3, less than 4.8 mg/100 ml and CH50, 13.0 U/ml) was noted there. No obvious episode of pharyngitis or skin infection were noted before the admission.

On admission, his body temperature was 37.0°C and blood pressure was 108/72 mmHg. Physical examination was unremarkable. No skin or mucosal lesions were observed. Urinalysis showed a specific gravity of 1.015, proteinuria of 297 mg/100 ml and 20–30 sediments of red blood cells per high-powered field. Urinary β_2 -microglobulin was 16.5 μ g/liter (normal < 250 μ g/liter). Laboratory studies revealed the following: white blood cells, 9560/ μ l with normal hemogram; hemoglobin, 11.7 g/100 ml; hematocrit, 35.1%; platelets, 382×10^3 / μ l; serum total protein, 5.4 g/100 ml; albumin, 3.2 g/100 ml; total cholesterol, 185 mg/100 ml; urea nitrogen, 14 mg/100 ml; creatinine, 0.9 mg/100 ml; sodium, 143 mEq/liter; potassium, 4.5 mEq/liter; chloride, 109 mEq/liter and calcium 8.1 mg/100 ml. Immunological studies showed the following values: IgG, 1372 mg/100 ml; IgA, 226 mg/100 ml; IgM, 143 mg/100 ml; C3, 21.4 mg/100 ml (normal range, 60–110 mg/100 ml); C4, 36.6 mg/100 ml (normal range, 15–40 mg/100 ml); CH50, 18.9 U/ml (normal range, 20–40 U/ml); anti-streptolysin O (ASO), 1:160 (normal, less than 1:320), anti-streptokinase (ASK), 1:1280 (normal, less than 1:5120) and C1q-binding circulating immunocomplexes, less than 1.5 μ g/ml (normal, less than 3.0 μ g/ml). Neither anti-nuclear antibody nor anti-DNA antibodies were detected. Serological tests for anti-neutrophil cytoplasmic antibodies

(proteinase 3 and myeloperoxidase), hepatitis virus (hepatitis B and C virus) and cryoglobulin were unremarkable. Creatinine clearance at the initial presentation decreased to 60.0 ml/minutes.

A percutaneous renal biopsy was done at hospital day 4. Portion of 29 glomeruli were seen by light microscopy of periodic acid-Schiff stained sections. Glomeruli showed diffuse endocapillary cell proliferation with leukocytic accumulation within the capillary loops (Fig. 1). Global and hilar lesion of segmental sclerosis were observed in 8 (28%) and 2 (7%) glomeruli in the specimen, respectively. A large region of the interstitium showed infiltrates of inflammatory cells associated with tubular atrophy. There were no vascular changes to suggest underlying systemic vasculitis. Immunofluorescence revealed 1+ of IgG, 1+ of IgM and C3 deposits in a granular pattern with mesangial and capillary distribution. IgA was not present in the specimen. An electron microscopic study revealed varying sized hemispherical-shaped subepithelial deposits and small-sized occasional mesangial deposits (Fig. 2). However, these glomerular alterations suggesting AGN did not seem to be compatible with his clinical course of unremitting proteinuria of long duration. Although his hematuria and hypocomplementemia spontaneously subsided by hospital day 30, proteinuria increased to nephrotic range. The creatinine clearance decreased to 44.0 ml/minutes. Oral prednisolone, 1 mg/kg daily was started, but it did not prove effective. A repeat renal biopsy was performed 4 months after the initial examination. Portion of 32 glomeruli were seen by light microscopy of periodic acid-Schiff stained sections. Global and hilar lesion of segmental sclerosis were observed in 17 (53%) and 13 (41%) glomeruli in the specimen, respectively. The remaining 2 glomeruli showed minor glomerular abnormalities. There were severe tubular atrophy and

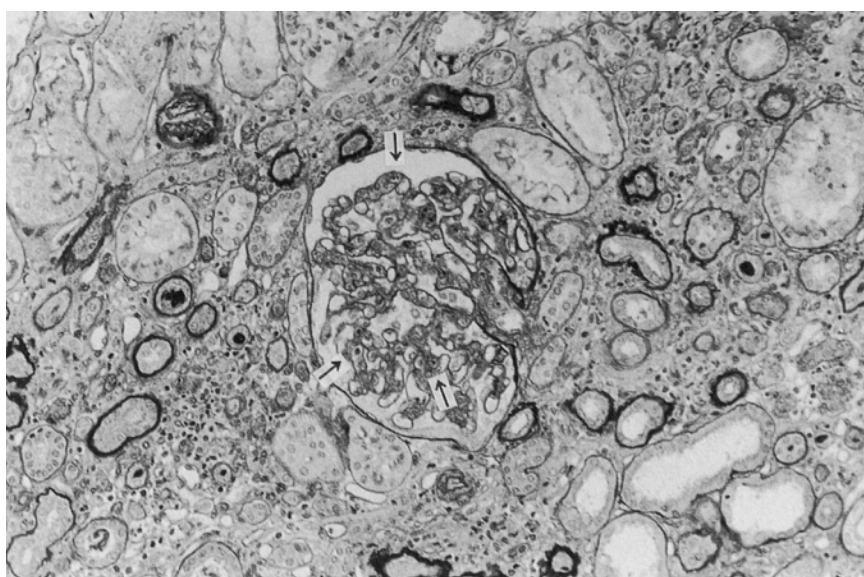


Fig. 1. Glomerulus showing endocapillary cell proliferation with neutrophils accumulation in the tuft (arrows). Interstitial infiltration and tubular atrophy are also seen (periodic acid-Schiff, $\times 200$).

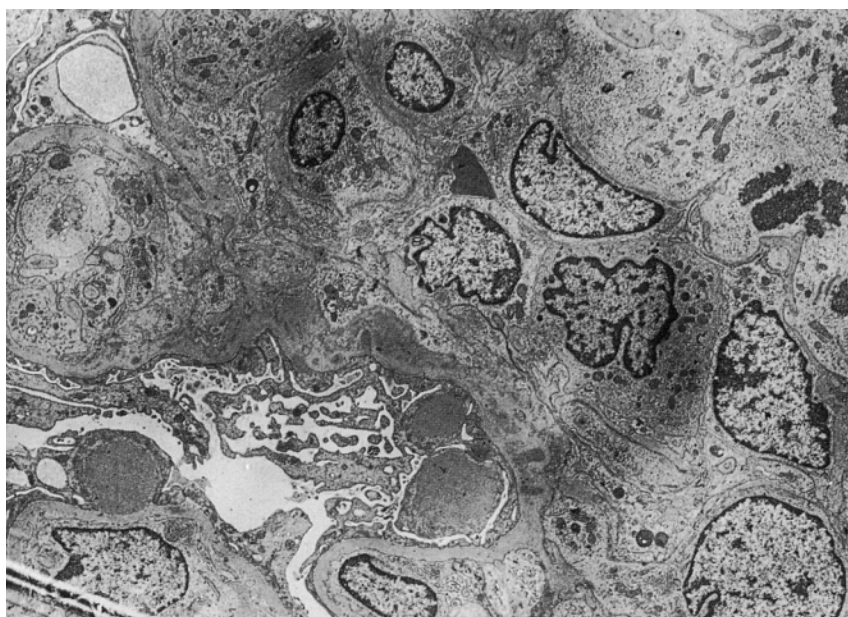


Fig. 2. Electron micrograph showing a large-sized hemispherical subepithelial deposits and occasional paramesangial deposits ($\times 3000$).

interstitial fibrosis. Immunofluorescence showed mesangial deposits of IgM (2+) and C3 (1+). Electron microscopic evaluation revealed occasional paramesangial deposits with complete disappearance of hump-shaped subepithelial deposits. These histologic alteration suggested that he had advanced FSGS.

His renal function progressively deteriorated, and he required peritoneal dialysis 1.5 years after the diagnosis was made.

DISCUSSION

A 3-year history of persistent proteinuria and the initial renal biopsy findings such as endocapillary proliferative glomerulonephritis with neutrophils accumulation prevented us from making a definite diagnosis in this case. Furthermore, he had a transient C3 depression in the sera and typical hump-shaped subepithelial deposits in the specimen for electron microscopy. Although his serum titers of ASO or ASK did not show a significant increase, these clinical and histological character indicated that he had typical AGN (Clark et al. 1988). However, his long-term clinical history as well as severe tubulointerstitial lesion observed in the specimen suggested that he had underlying CGN. Actually, the second renal biopsy findings suggesting FSGS seemed to be compatible with the unremitting proteinuria of long duration. It has been reported that children with FSGS without NS in Japan are often found via urine mass screening of school children (Yoshikawa et al. 1991). Hence, it is considered that he had had asymptomatic "silent" FSGS preceding the episode of AGN, and that the episode might affect histologic alteration of FSGS, and led to emergence of typical clinical manifestations of FSGS.

So far there are several published reports to describe superimposed nephritis

(Bertani et al. 1986; Gallego et al. 1991; Kamiya et al. 1991; Kubo et al. 1994; Scully et al. 1995). From the literature, patients with diabetic glomerulopathy often develop membranous nephropathy, and that the association may be responsible for preexisting glomerular alteration which favors an immune reaction in the subepithelial space (Bertani et al. 1986). Concerning the superimposition of AGN on some kind of CGN, it is thought to be on the basis of chance. The association of AGN and some kind of CGN also has been reported to date (Bertani et al. 1986; Kamiya et al. 1991; Kubo et al. 1994; Scully et al. 1995). However, to the best of our knowledge, the association of AGN and FSGS has not been reported previously.

Although steroid-resistant FSGS is known to be a lesion associated with an unfavorable outcome (Korbet et al. 1994), in the present case, AGN may have attributed to subsequently progression to end-stage renal failure over a short period. Kubo et al. (1994) reported a patient with diabetic nephropathy who developed end-stage renal failure after the episode of AGN. From these observation, it is suggested that AGN may affect histologic alterations of underlying CGN, and may cause acute exacerbation of the CGN in the proportion of patient. Although the prognosis of AGN itself is known to be favorable (Clark et al. 1988), more attention should be paid to AGN in case of acute exacerbation in patients with CGN.

Reference

- 1) Bertani, T., Mecca, G., Sacchi, G. & Remuzzi, G. (1986) Superimposed nephritis; A separate entity among glomerular diseases? *Am. J. Kidney Dis.*, **7**, 205-212.
 - 2) Clark, G., White, R.H.R., Glasgow, E.F., Chantler, C., Cameron, J.S., Gill, D. & Comley, L.A. (1988) Poststreptococcal glomerulonephritis in children: Clinicopathological correlations and long-term prognosis. *Pediatr. Nephrol.*, **2**, 381-388.
 - 3) Gallego, N., Teruel, J.L., Mampaso, F., Gonzalo, A. & Ortuno, J. (1991) Acute interstitial nephritis superimposed on glomerulonephritis: A report of a case. *Pediatr. Nephrol.*, **5**, 229-231.
 - 4) Kamiya, T., Tanizawa, T., Wada, H., Kawaguchi, S., Arimoto, K., Taki, M., Omori, H. & Kosaka, A. (1991) Poststreptococcal acute glomerulonephritis on IgA glomerulonephritis. A case report. *Jin to Toseki (Kidney and Dial., Tokyo)*, **30**, 781-784. (in Japanese)
 - 5) Korbet, S.M., Schwartz, M.M. & Lewis E.J. (1994) Primary focal segmental glomerulosclerosis: Clinical course and response to therapy. *Am. J. Kidney Dis.*, **23**, 773-783.
 - 6) Kubo, M., Takeda, K. & Harada, A. (1994) Clinical analysis of cases with acute exacerbation of chronic renal failure. *Nippon Jinzo Gakkaisi (Jpn. J. Nephrol.)* **36**, 163-171. (in Japanese with English abstract)
 - 7) Scully, R.E., Mark, E.J., McNeely, W.F. & McNeely, B.U. (1995) Case records of the Massachusetts General Hospital. *N. Engl. J. Med.*, **332**, 1083-1089.
 - 8) Yoshikawa, N., Kitagawa, K., Ohta, K., Tanaka, R. & Nakamura, H. (1991) Asymptomatic constant isolated proteinuria in children. *J. Pediatr.*, **119**, 375-379.
-