Tohoku J. Exp. Med., 2005, **205**, 27-36

Protective Effects of Prenatal Administration of Folic Acid on Retinoic Acid-Induced Cellular Damages of Meckel's Cartilage in Rats

DENIZ FIRAT, LEYLA KUNTSAL[1] and YIGIT SIRIN

Department of Oral Surgery, School of Dentisry, and [1]Department of Histology and Embryology, School of Medicine, Istanbul University, Istanbul, Turkey

FIRAT, D., KUNTSAL, L. and SIRIN, Y. *Protective Effects of Prenatal Administration of Folic Acid on Retinoic Acid Induced Damages of Meckel's Cartilage in Rats*. Tohoku J. Exp. Med., 2005, **205** (1), 27-36 —— Craniofacial malformations are among the most common congenital deformities. Meckel's cartilage plays a major role in the development of the mandible and is highly susceptible to maternal teratogenic drug use. We therefore investigated possible protective effects of prenatal administration of folic acid on a retinoic-acid induced maxillofacial defect model. Sprague-Dawley pregnant female rats (n = 36) were used in this study. Retinoic acid was administered orally at the dose of 40, 60, or 80 mg/kg respectively on gestational day 8. Folic acid of 4.0 mg/kg was injected intraperitoneally on 7th, 8th and 9th days of pregnancy. Animals were sacrificed on the day 17th. Administration of retinoic acid at all doses resulted in statistically significant decreases in mean fetal weight and mean fetal height and the increase in mortality rate, and caused severe ultrastructural damages in Meckel's cartilage. Folic acid administration prevented the decrease in mean fetal weight and height of the embryos treated with retinoic acid of 40 mg/kg. In addition, there was a marked decrease in the number of degenerated chondrocytes and an improvement in the structure of granular endoplasmic reticulum along with intact nuclei. We conclude that folic acid has protective effects on retinoic acid-induced intracellular damages in Meckel's cartilage ——— retinoic acid; Meckel's cartilage; folic acid; ultrastructural; rat

Congenital deformities are leading causes of infant mortality and childhood morbidity, affecting 2-3% of all newborns (WHO 2001). Abnormal development of the craniofacial structure that represents approximately 1% of human birth defects is associated with genetic background and environmental factors, as well as maternal teratogenic drug exposure (Murray and Schutte 2004). Among these substances, retinoic acid (RA), an analogue of vitamin A, is commonly used in dermatology for treatment of severe cystic acne, ichtyosis and keratinizing dermatoses (Ellis and Krach 2001). Endogenous RA is essential for numerous processes of life such as vision (Wagner

Received July 21, 2004; revision accepted for publication November 9, 2004.
Address for reprints: Dr. Deniz Firat, Istanbul Universitesi Dishekimligi Fak, Agiz-Dis Cene Hast. ve Cerrahisi, Anabilim Dalı Çapa, Istanbul, Turkey.
e-mail: rdfirat@yahoo.com

et al. 2000), immune function, reproduction (Napoli 1999; Livera et al. 2002) and maintenance of normal growth patterns, predominantly in higher eukaryotic organisms which can not synthesize it independently (Ward and Morriss-Kay 1997). In contrast, it is widely accepted that excessive RA intake during pregnancy results in a variety of craniofacial malformations including exencephaly, hydrocephalus, cleft lip with or without cleft palate and shortening of maxilla and mandible, depending upon the dosage and gestational stage at the time of drug administration (Cohlan 1953; Kochhar and Aydelotte 1974; Lammer et al. 1985; Emmanouil-Nikoloussi et al. 2000; Yu et al. 2003). Cephalic neural crest, which has been held primarily responsible for RA-induced damage on fetal development (Ruberte et al. 1993), is a pluripotent cell population derived from the lateral ridges of the neural plate in the early stage of embryogenesis (Bronner-Fraser 1993). During normal craniofacial morphogenesis, these cells migrate extensively through the embryo to populate branchial archs (Chai et al. 2000) that develops into most of the facial structures including mandible (Plant et al. 2000).

The segments of hyaline cartilage derived from the first branchial arch are known as Meckel's cartilage (MC) in mammals and disappear at the neonatal stage of the development (Ishizeki et al. 1999). Originating from neural crest cells, MC contributes to the formation of mandible by acting as a site of ossification center around which mandibular bone develops and by providing support to the osseous framework (Richman and Diewert 1988; Tomo et al. 1997).

Maternal periconceptional supplementation with B group vitamins, especially folic acid (FA), is a well-established preventive approach to the neural tube defects, discovered long before biochemical basis of these malformations has been studied extensively (Green 2002; Krapels et al. 2004). Shaw et al. (1995) reported that FA supplementation in women of child-bearing age had resulted in 25-50% reduction in risk of having offspring with orofacial cleft. Similarly, teratogenically induced facial defects have been shown to decrease by FA administration in animal studies (Bienengraber et al. 2001).

As far as we know, there is no study about the influence of FA on teratogen-stimulated cellular alterations of MC alone. The purpose of this study is to determine whether prenatal administration of FA has protective effects on intracellular components of MC in a RA-induced animal defect model.

Materials and Methods

Animals

Adult virgin Sprague-Dawley female rats, weighing 220 ± 10 g obtained from Istanbul University, Institute for Experimental Medical Research, were used in this study (n = 36). Following several days of acclimatization, animals were housed in metallic cages with males (male to female ratio of 2:3). They were mated from 6 p.m. to 6 a.m.; the day of vaginal plug detection was designated gestational day (GD) 0 of pregnancy. Throughout the study, animals were kept in a temperature (23 ± 1°C) and humidity (60-80%) controlled room under regular light-dark conditions. They were fed with standard laboratory rat chow and water ad libitum. All procedures were reviewed and approved by the Institutional Animal Care and Use Committee at the Istanbul University, Institute for Experimental Medical Research.

Experimental protocol

Pregnant female rats were divided into seven groups (6 rats for the control and 5 rats in each of six experimental groups). Retinoic acid (RA) (Isotretinoin, Roaccutane®, Hoffmann-La Roche Ltd., Basel, Switzerland) was suspended in corn-oil and was administered orally at the dose of 40, 60 or 80 mg/kg respectively; on GD 8 to fifteen experimental animals, forming RA-treated groups (five rats per dose). Another fifteen rats received equal doses of RA on the same GD and they were additionally administered intraperitoneal folic acid (FA) of 4.0 mg/kg (Reynols et al. 2003) (Folvite®, Bedford Laboratories Inc., Bedford, England) on GD 7, 8 and 9 forming FA-treated groups. In order to explore whether corn-oil or FA has teratogenic effects, rats were treated with sterile saline corn oil, or FA on the similar GD schedule (two rats for each application). Animals were sacrificed with prolonged ether anesthesia on GD 17. Following an abdominal incision, uterus was removed. Implantation sites, number of intact embryos and resorbed embryonic masses were counted.

TABLE 1. *Effects of retinoic acid and folic acid on pregnancy outcome and embryo status. Prenatal folic acid administration significantly increased mean fetal weight and height of the embryos treated with retinoic acid of 40 mg/kg.*

Group	Number of pregnant rats	Number of implants	Number of intact fetuses	Number of dead and/or resorbed fetus	% Mortality	Mean fetal weight ± S.D. (g)	Mean fetal height ± S.D. (cm)
Control	6	69	67	2	2.8	2.21 ± 0.20	2.33 ± 0.17
RA of 40 mg/kg	5	57	52	5	8.7	1.32 ± 0.12	1.56 ± 0.15
RA of 60 mg/kg	5	54	45	9	16.6	0.64 ± 0.14	1.36 ± 0.19
RA of 80 mg/kg	5	56	43	13	23.2	0.54 ± 0.18	1.37 ± 0.12
RA of 40 mg/kg + FA	5	59	51	8	6.7	1.73 ± 0.16*	1.79 ± 0.09*
RA of 60 mg/kg + FA	5	53	42	11	20.7	0.61 ± 0.12	1.43 ± 0.14
RA of 80 mg/kg + FA	5	51	36	15	29.4	0.56 ± 0.10	1.45 ± 0.11

* $p < 0.001$.

Macroscopically intact embryos were immediately weighed and their heights were measured. Mandibles were removed from the heads under a dissecting microscope and were processed for histological examination. Dosage and application information are summarized in Table 1.

Histological study

All of the mandibles of macroscopically intact embryos were fixed in 2.5% cacodylate buffered glutaraldehyde solution for microscopic examination, and postfixed in 2% osmic acid for an hour (Robinson and Gray 1996). Following dehydration through a graded series of alcohol, they were embedded in Epon 812 (Fluka AG, Buchs, Switzerland). At least four blocks were obtained from every pregnant rat. The blocks were sectioned using LKB Ultramicrotome (Stockholm, Sweden). In order to find exact position of MC in mandibular tissues, thick sections were stained with toluidin blue and observed. Ultra thin sections selected from appropriate regions were contrasted with lead citrate and uranyl acetate, and examined under an electron microscope (JEOL 1011, Tokyo).

Statistical analysis

Mortality rates are presented as percentage of embryos. Weight and height data obtained from all groups are reported as mean ± S.D. Statistical analysis was carried out on GraphPad Prism® V.3 software (GraphPad Software Inc., San Diego, CA, USA). We used χ^2 and Fisher's exact tests to compare mortality ratio between groups. Changes in embryo weight and height were examined with descriptive statistical methods as well as one-way analysis of variance test between group comparisons and Turkey's multiple comparison tests in subgroup comparisons. The results were evaluated in a confidence interval of 95 % and $p < 0.05$ was considered as statistically significant.

RESULTS

Quantitative measurements

All animals have tolerated experimental procedures well, and no drug associated mortality of pregnant rat was observed. Since there was no difference among three types of controls, these groups were evaluated as a single entity. Never-

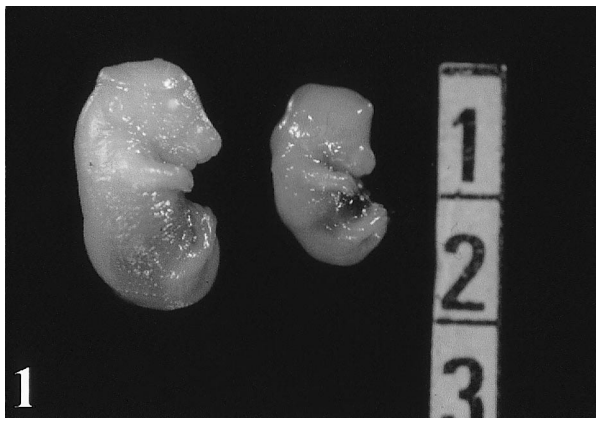

Fig. 1. Macroscopic view of control (left) and RA (40 mg/kg) treated embryos.

theless, RA had substantial effects on embryos (Fig. 1): mortality rates in groups treated with RA of 40, 60 or 80 mg/kg (8.7%, 16.6% or 23.2% respectively), were significantly higher than control group (2.8%) ($p < 0.001$). Furthermore, mean fetal weights (1.32 ± 0.12 g, 0.64 ± 0.14 g, 0.54 ± 0.18 g, respectively) and mean fetal heights (1.56 ± 0.15 cm, 1.36 ± 0.19 cm, 1.37 ± 0.12 cm, respectively) of the same groups were significantly lower tham these of the control group (2.21 ± 0.20 g) and height 2.33 ± 0.17 cm) ($p < 0.001$) for both, as summarized in Table 1.

Supplemental FA administration to the animals given RA of 40, 60 or 80 mg/kg had no effect on mortality rates, since death ratios of the embryos of FA treated groups (6.7%, 20.7%, 29.4%, respectively) were still significantly higher than those of the control group ($p < 0.001$). On the other hand, FA supplementation on animals treated with RA (40 mg/kg), increased mean body weight (1.73 ± 0.16 g) and height (1.79 ± 0.09 cm), when compared to the treated with RA (40 mg/kg) alone ($p < 0.01$).

Histological observations

Condensed mesenchimal cells of the mandibular prominence were typical along with regular alignment of normal chondrocytes of MC which is surrounded by an intact and well-developed perichondrium in thick sections taken from the embryos of control group (Fig. 2A).

Perichondrial region of the control group was observed to be full of long, spindle-shaped fibroblasts in several layers with abundant rough endoplasmic reticulum. The chondrocytes with large and clear nuclei containing a central prominent nucleoulus, were located in lacunae, within the cartilage matrix rich in collagen fibers. Numerous cell processes were noticed extruding from the cell membrane into the matrix. Organelles such as rough endoplasmic reticulum

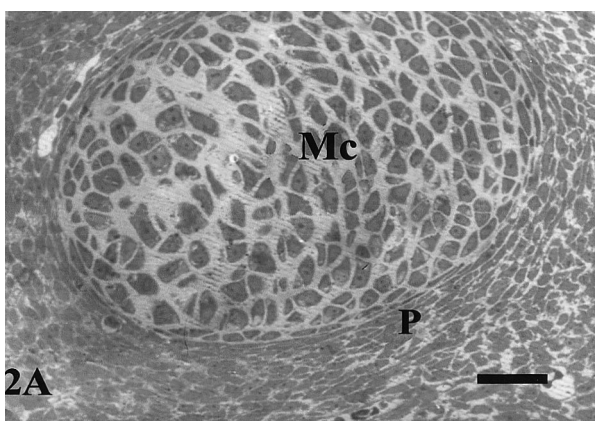

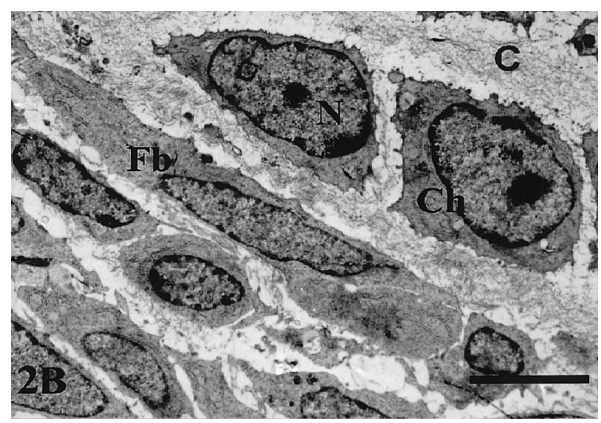

Fig. 2. Control group: Typical histological features of Meckel's cartilage.
A: General view of Meckel's cartilage (MC) surrounded by intact perichondrium (P) (Plastic section, toluidine blue; × 310)
B: Fibroblasts and chondrocytes located in cellular matrix rich in collagen fibers.
Fb, Fibroblast; Ch, Chondrocyte; N, Nucleus; C, Collagen (Electron mic; × 5000).
Bar in A, 20 μm; bar in B, 5 μm.

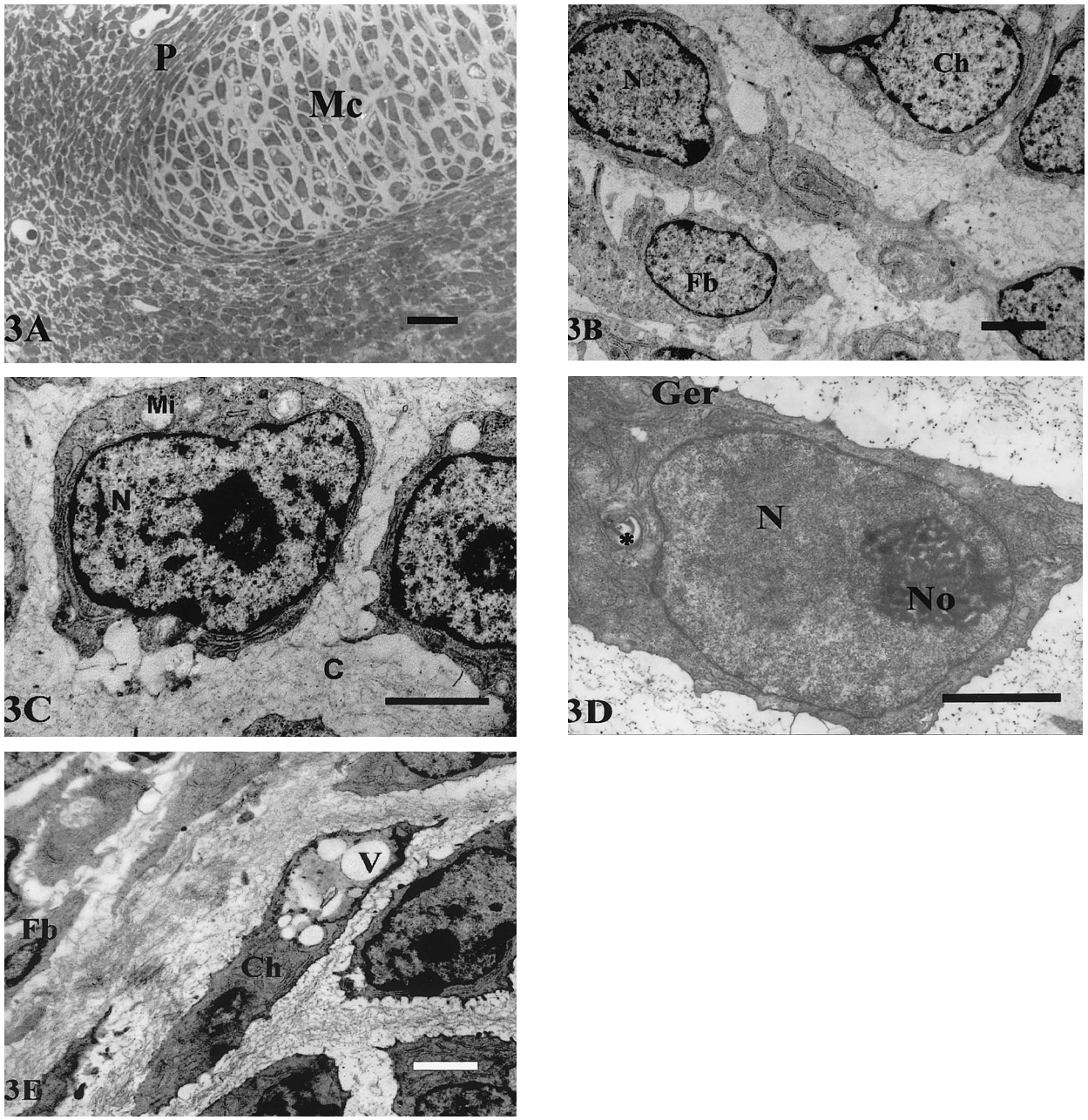

Fig. 3. Experimental groups treated with retinoic acid showing severe intracellular degeneration.
A: Note irregular vacuolar aspect of chondrocytes in RA treated (40 mg/kg) group. MC, Meckel's cartilage; P, Perichondrium (Plastic section, toluidine blue × 310).
B: Morphological degeneration in fibroblasts and chondrocytes. Fb, Fibroblast; Ch, Chondrocyte; N, Nucleus (Electron mic; × 6000).
C: Marked decrease in the number of microvillus covering the cell membrane and swollen mitochondria (Mi) with damaged cristae. N, Nucleus; C, Collagen (Electron mic; × 7500).
D: Severe degeneration in nucleus (N), note dissociation of the fibrillar and granular components. No, Nucleolus; Ger, Granular endoplasmic reticulum; *, Myelin-like figures (Electron mic; × 7500).
E: Extensive intracytoplasmic degeneration and large, empty vacuoles (V) without organelles in the chondrocyte (Ch) of 60 mg/kg RA treated group.
Fb, Fibroblast; N, Nucleus. (Electron mic; × 5000).
Bar in A, 20 μm; bars in B-E, 2 μm.

with well-developed membrane, free ribosomes, golgi complex and large mitochondrion were clearly visible throughout the cytoplasm (Fig. 2B). Some of these cells contained vesicules filled with flocculent material, dilated saccules and vacuoles presumably related to collagen synthesis.

The perichondrium around MC of the RA 40 (mg/kg)-treated group was still intact and chondrocytes were observed to yet have arranged in a columnar appearance, however, many of them had lost their ordinary shape presenting an irregular vacuolar aspect (Fig. 3A). Ultra-thin sections revealed that the fibroblasts were expanded and turned into elliptical form with marked degeneration on their cell membrane, when compared to those of controls. Furthermore, the chondrocytes within the cartilage matrix were mostly degenerated (Fig. 3B). These cells were observed to exhibit polygonal morphology instead of their typical round shape. There was also a marked decrease in the number of microvillus on cell membrane (Fig. 3C). Some of the chondrocytes had pyknotic nuclei indicating an ongoing degeneration process. In addition, dissociation of fibrillar and granular components of nucleoulus was observed. Irregularly shaped large spaces without recognizable organelles were seen in the cytoplasm of chondrocytes, some of them containing myelin-like figures (Fig. 3D). Similarly, dilated

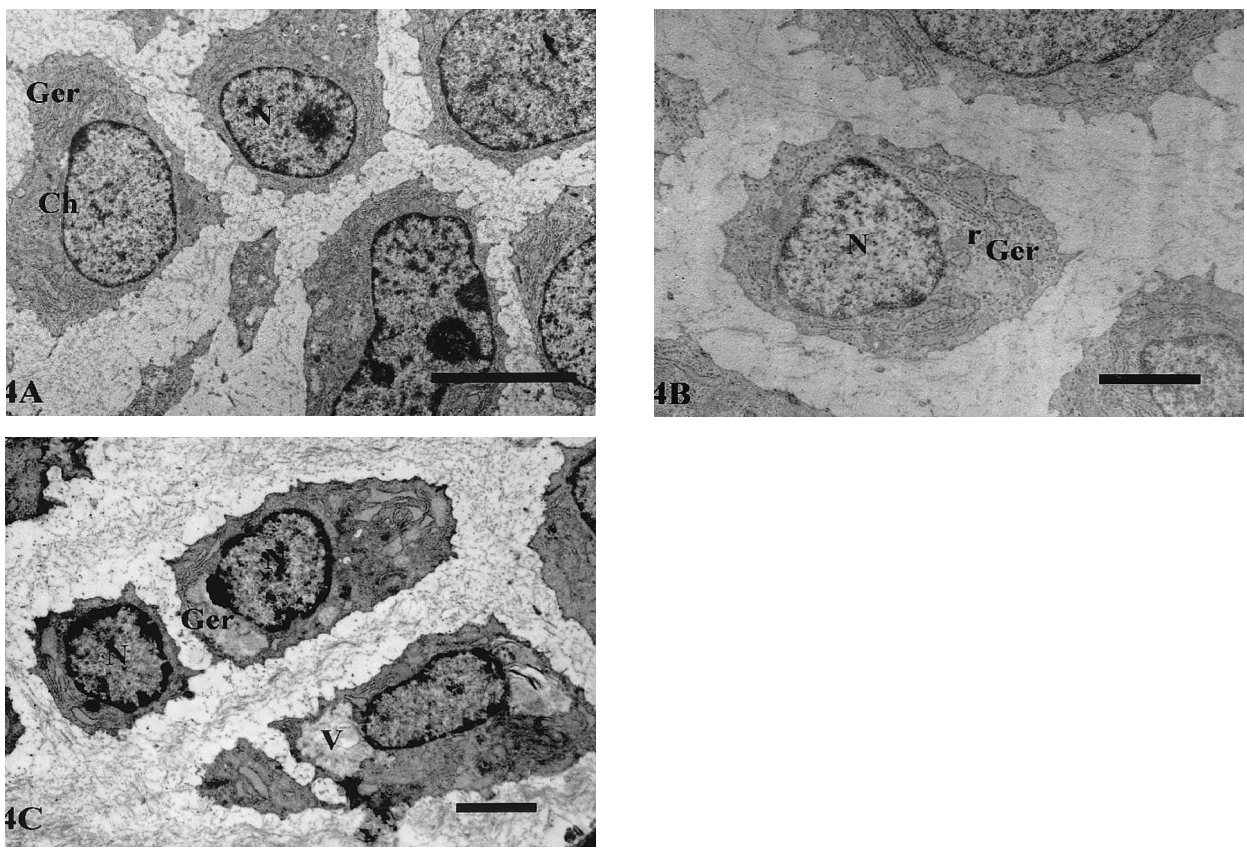

Fig. 4. Intracellular effects of folic acid administration in MC of RA treated embryos.
A: Electron micrograph of chondrocytes in FA-treated group, no evidence of degeneration. Ch, Chondrocyte; N, Nucleus; Ger, Granular endoplasmic reticulum (Electron mic; × 6000).
B: Intact view of intracytoplasmic organelles of chondrocyte in the same group. N, Nucleus; R, Ribosomes; Ger, Granular endoplasmic reticulum. (Electron mic; × 6000).
C: Persisting vacuolar degeneration (V) and dilated granular endoplasmic reticulum (Ger) in the chondrocytes of 60 mg RA + FA treated group. N, Nucleus. (Electron mic; × 6000). Bar in A, 5 μm; bars in B and C, 2 μm.

rough endoplasmic reticulum, swollen mitochondrion with disorganized cisternae and marked decrease in golgi complex evidenced the substantial effects of RA on intracellular components of MC.

Sections taken from the groups treated with RA of 60 or 80 mg/kg showed far more extensive findings of degeneration in fibroblasts of the perichondrium and intracellular organelles of chondrocytes forming MC, with remarkable deterioration in both nuclear and nucleolar structure (Fig. 3E).

Concomitant administration of FA with RA of 40 mg/kg had resulted with an improvement in the cellular structure of MC (Fig. 4A). There was a considerable decrease in the amount of degenerated chondrocytes, and intracytoplasmic organelles were structurally intact, sharing similar histological appearance with control group (Fig. 4B). On the other hand, FA administration was not able to prevent damages in the groups administered RA of 60 or 80 mg/kg as there was no noticable change in intracellular morphology when compared to the groups treated with same doses of RA alone (Fig. 4C).

Discussion

Abnormal development of the craniofacial structure has long been considered as an area of particular interest. Medical literature concerning teratological studies has several examples of species and strain differences regarding sensitivity to chemically induced malformations (Collins and Mao 1999). Excessive amount of exogenous RA is a potential teratogen, which is rapidly absorbed from the duodenum and bound to plasma albumin due to its high lipophilicity (Kurlandsky et al. 1995). Cellular retinol binding proteins transport RA in the cytoplasm where it can either be destabilized by cellular retinoic acid binding proteins (CRABPs) or enter the nucleus and bind to the nuclear retinoic acid receptors (RAR and/or RXR), causing activation of specific genes (Morriss-Kay and Ward 1999). Migrating cranial neural crest cells, which will later reside within maxillary and mandibular prominences show high affinity to RA (Brickell and Thorogood 1997), thereby leading to a impairment of eye, ear and facial development (Louryan et al. 1992). From this hypothetical point of view, RA-induced teratogenesis provides a useful experimental model for studying both cellular alterations of craniofacial structures and underlying pathogenesis of specific conditions like DiGeorge and Treacher-Collins syndromes which demonstrate clinical similarities to the RA embryopathy (Johnston and Bronsky 1991).

The developmental stage of the embryo reflects critical time period for specific malformations (Shenefelt 1972). Our findings in embryos treated with RA on GD 8 were consistent with those of Granstrom et al. (1990) and Jarvis et al. (1990) whom have reported similar changes on GD 8 and 9, respectively. Moreover, Padmanabhan and Ahmed (1997) have pointed out that most striking fetal effect of RA concentrated on 8th day of pregnancy. The increased susceptibility of MC to RA on this day, as well as other first branchial arch derivatives, may be correlated with high levels of CRABP which acts as a moderator of RA fluctuations (Ward and Morriss-Kay 1997), in regions where cranial neural crest cells are known to migrate (Dencker et al. 1987).

RA treatment had dramatic effects in body weights, heights and mortality rates of the embryos at all doses, as also described by Ikemi et al. (1995) and Gunning et al. (1993). Granstrom and Kullaa-Mikkonen (1990) have emphasized that RA of 60 mg/kg or more induced high incidence of fetal death and resorption, whereas 40 mg/kg was suitable for litters to be brought to delivery. Interestingly, we detected no significant changes in these values between RA of 60 or 80 mg/kg. Even though our sample size is relatively small to make a direct assessment, a possible explanation for this peak level produced above RA of 40 mg/kg is the saturation of the binding and metabolic activities of CRABP I, enabling more RA to reach the nuclear receptors (Bailey and Siu 1988; Ruberte et al. 1993). Our observations in group where RA of 40 mg/kg and FA were applied together disclosed that the prenatal FA administration had increased mean body weight and height of the embryos. Reynolds et al. (2003) obtained a

significant decrease in cleft palate incidence using similar dose of FA and proposed a relationship between the signaling pathways of RA which has been shown to perturb methyl group metabolism in DNA synthesis (Naitoh et al. 1998), and the role of FA as a methyl donating co-factor.

RA treatment was observed to induce severe cellular damage in a dose-dependent manner. Our microscopic findings of larger nuclei, less numerous isogenous nests and degenerated chondrocytes were consistent with the observations of Granstrom et al. (1990), and with Lopes et al. (1982) who had investigated the morphological changes of MC in rats given vitamin A of 150,000 units on GD 10. Wilkinson and Poswillo (1991) found no sign of decrease in the coronal size of MC in rats given vitamin A of 50,000 units whereas Granstrom et al. (1991) showed a marked reduction, also postulating a possible process of pathological pre-term endochondral ossification based on earlier calcification of cartilaginous tissue. Nevertheless, these two studies, as well as most of the others, have disregarded the fact that MC is a dynamic structure that undergoes resorption. Inevitably, the GD in which the animals had been sacrificed is of utmost importance for a study concerning cellular alterations of MC; otherwise, it is possible to confuse the ultrastructural effects of exogenous RA with those of natural resorption process. Our observations in embryos of experimental groups on GD 17 did not reveal sign of extensive early calcification in the condensed mesenchimal area surrounding MC.

Polygonal shape detected in chondrocytes which normally have round form, was comparable to morphological alterations reported in limb bud cell cultures in response to RA treatment (Underhill and Weston 1998). Moreover, we observed severe decrease in the number of microvillus on cell membrane which would probably affect cell process network (Sulik et al. 1987). There was substantial dilatation on rough endoplasmic reticulum and empty vacuoles within the chondrocytes of MC which may be linked to the ability of Vitamin A and its analogues to insert into biological membranes, thereby altering fluid accumulation (Glauert et al. 1963). Contrarily, ultrastructural observation of the group treated with RA of 40 mg/kg and FA revealed no dissociation in nucleolar compartment and cytoplasmic organelles were structurally intact, indicating that FA administration provides protection against RA mediated intracellular damages of MC. Furthermore, FA of 4.0 mg/kg we used in our study resides within therapeutic ranges since there was no pathological alteration neither in body weight and height nor in histological appearance of MC of the embryos born to mothers treated with FA alone.

Conclusion

Prenatal administration of FA has protective effects on RA-induced cellular damages in MC of rats, a key structure in the growth patterns of mandible. As a result of multi-factorial background of teratogenesis, experimental studies focusing on the relationship between dosage of FA and embryonic stage are needed in order to clarify the role of FA in mandibular cartilage development.

References

Bailey, J.S. & Siu, C.H. (1988) Purification and partial characterization of a novel binding protein for retinoic acid from neonatal rat. *J. Biol. Chem.*, **263**, 9326-9332.

Bienengraber, V., Malek, F.A., Moritz, K.U., Fanghanel, J., Gundlach, K.K. & Weingartner, J. (2001) Is it possible to prevent cleft palate by prenatal administration of folic acid? An experimental study. *Cleft Palate Craniofac. J.*, **38**, 393-398.

Brickell, P. & Thorogood, P. (1997) Retinoic acid and retinoic acid receptors in craniofacial development. *Semin. Cell. Dev. Biol.*, **8**, 437-443.

Bronner-Fraser, M. (1993) Neural crest cell migration in the developing embryo. *Trends Cell. Biol.*, **11**, 392-397.

Chai, Y., Jiang, X., Ito, Y., Bringas, P., Han, J., Rowitch, D.H., Soriano, P., Mcmahon, A.P. & Sucov, H.M. (2000) Fate of the mammalian cranial neural crest during tooth and mandibular morphogenesis. *Development*, **127**, 1671-1679.

Cohlan, S.Q. (1953) Excessive intake of vitamin A as a cause of congenital anomalies in the rat. *Science,* **117**, 535-536.

Collins, M.D. & Mao, G.E. (1999) Teratology of retinoids. *Annu. Rev. Pharmacol. Toxicol.*, **39**,

399-430.

Dencker, L., d'Argy, R., Danielsson, B.R., Ghantous, H. & Sperber, G.O. (1987) Saturable accumulation of retinoic acid in neural and neural crest derived cells in early embryonic development. *Dev. Pharmacol. Ther.*, **10**, 212-223.

Ellis, C.N. & Krach, K.J. (2001) Uses and complications of isotretinoin therapy. *J. Am. Acad. Dermatol.,* **45**, 150-157.

Emmanouil-Nikoloussi, E.N., Goret-Nicaise, M., Foroglou, C.H., Katsarma, E., Dhem, A., Dourov, N., Persaud, T.V. & Thliveris, J.A. (2000) Craniofacial abnormalities induced by retinoic acid: a preliminary histological and scanning electron microscopic (SEM) study. *Exp. Toxicol. Pathol.*, **52**, 445-453.

Glauert, A.M., Daniel, M.R., Lucy, J.A. & Dingle, J.T. (1963) Studies on the mode of action of excess of vitamin A. VII. Changes in the fine structure of erythrocytes during haemolysis by vitamin A. *J. Cell. Biol.*, **17**, 111-121.

Granstrom, G., Jacobsson, C. & Magnusson, B.C. (1991) Enzyme histochemical analysis of craniofacial malformations induced by retinoids. *Scand. J. Plast. Reconstr. Surg. Hand. Surg.,* **25**, 133-141.

Granstrom, G. & Kullaa-Mikkonen, A. (1990) Experimental craniofacial malformations induced by retinoids and resembling branchial arch syndromes. *Scand. J. Plast. Reconstr. Surg. Hand. Surg.*, **24**, 3-12.

Granstrom, G., Kullaa-Mikkonen, A. & Zellin, G. (1990) Malformations of the maxillofacial region induced by retinoids in an experimental system. *Int. J. Oral Maxillofac. Surg.*, **19**, 167-171.

Green, N.S. (2002) Folic acid supplementation and prevention of birth defects. *J. Nutr.,* **132**, 2356-2360.

Gunning, D.B., Barua, A.B. & Olson, J.A. (1993) Comparative teratogenicity and metabolism of all-trans retinoic acid, all-trans retinoyl beta-glucose, and all-trans retinoyl beta-glucuronide in pregnant Sprague-Dawley rats., *Teratology,* **47**, 29-36.

Ikemi, N., Kawata, M. & Yasuda, M. (1995) All-trans-retinoic acid-induced variant patterns of palatal rugae in Crj:SD rat fetuses and their potential as indicators for teratogenicity. *Reprod. Toxicol.*, **9**, 369-377.

Ishizeki, K., Saito, H., Shinagawa, T., Fujiwara, N. & Nawa, T. (1999) Histochemical and immunohistochemical analysis of the mechanism of calcification of Meckel's cartilage during mandible development in rodents. *J. Anat.*, **194**, 265-277.

Jarvis, B.L., Johnston, M.C. & Sulik, K.K. (1990) Congenital malformations of the external, middle, and inner ear produced by isotretinoin exposure in mouse embryos. *Otolaryngol. Head Neck Surg.*, **102**, 391-401.

Johnston, M.C. & Bronsky, P.T. (1991) Animal models for human craniofacial malformations. *J. Craniofac. Genet. Dev. Biol.*, **11**, 277-291.

Kochhar, D.M. & Aydelotte, M.B. (1974) Susceptible stages and abnormal morphogenesis in the developing mouse limb, analysed in organ culture after transplacental exposure to vitamin A (retinoic acid). *J. Embryol. Exp. Morphol.*, **31**, 721-734.

Krapels, I.P., van Rooij, I.A., Ocke, M.C., van Cleef, B.A., Kuijpers-Jagtman, A.M. & Steegers-Theunissen, R.P. (2004) Maternal dietary B vitamin intake, other than folate, and the association with orofacial cleft in the offspring. *Eur. J. Nutr.*, **43**, 7-14.

Kurlandsky, S.B., Gamble, M.V., Ramakrishnan, R. & Blaner, W.S. (1995) Plasma delivery of retinoic acid to tissues in the rat. *J. Biol. Chem.*, **270**, 17850-17857.

Lammer, E.J., Chen, D.T., Hoar, R.M., Agnish, N.D., Benke, P.J., Braun, J.T., Curry, C.J., Fernhoff, P.M., Grix, A.W., Lott, I.T., Richard, J.M. & Sun, S.C. (1985) Retinoic acid embryopathy. *N. Engl. J. Med.*, **313**, 837-841.

Livera, G., Rouiller-Fabre, V., Pairault, C., Levacher, C. & Habert, R. (2002) Regulation and perturbation of testicular functions by vitamin A. *Reproduction,* **124**, 173-180.

Lopes, R.A., Souza, M.L. & Azoubel, R. (1982) Morphometric study of malformations induced by hypervitaminosis A on rat fetus Meckel cartilage, maxillary bone and mandible. *Anat. Anz.*, **152**, 329-336.

Louryan, S., Glineur, R. & Dourov, N. (1992) Induced and genetic mouse middle ear ossicular malformations: a model for human malformative ossicular diseases and a tool for clarifying their normal ontogenesis. *Surg. Radiol. Anat.*, **14**, 227-232.

Morriss-Kay, G.M. & Ward, S.J. (1999) Retinoids and mammalian development. *Int. Rev. Cytol.,* **188**, 73-131.

Murray, J.C. & Schutte, B.C. (2004) Cleft palate: players, pathways, and pursuits. *J. Clin. Invest.*, **113**, 1676-1678.

Naitoh, H., Mori, C., Nishimura, Y. & Shiota, K. (1998) Altered expression of retinoic acid (RA) receptor mRNAs in the fetal mouse secondary palate by all-trans and 13-cis RAs: implications for RA-induced teratogenesis. *J. Craniofac. Genet.*

Dev. Biol., **18**, 202-210.

Napoli, J.L. (1999) Interactions of retinoid binding proteins and enzymes in retinoid metabolism. *Biochim. Biophys. Acta,* **1440**, 139-162.

Padmanabhan, R. & Ahmed, I. (1997) Retinoic acid-induced asymmetric craniofacial growth and cleft palate in the TO mouse fetus. *Reprod. Toxicol.,* **11**, 843-860.

Plant, M.R., MacDonald, M.E., Grad, L.I., Ritchie, S.J. & Richman, J.M. (2000) Locally released retinoic acid repatterns the first branchial arch cartilages in vivo. *Dev. Biol.*, **222**, 12-26.

Reynolds, P.R., Schaalje, G.B. & Seegmiller, R.E. (2003) Combination therapy with folic acid and methionine in the prevention of retinoic acid-induced cleft palate in mice. *Birth Defects Res. Part A Clin. Mol. Teratol.,* **67**, 168-173.

Richman, J.M. & Diewert, V.M. (1988) The fate of Meckel's cartilage chondrocytes in ocular culture. *Dev. Biol.,* **129**, 48-60.

Robinson, G. & Gray, T. (1996) Electron microscopy 2: Practical procedures. In: *Theory and Practice of Histological techniques*, edited by J.D. Bancroft & A. Stevens, London, New York, Madrid, San Francisco, Churchill Livingstone, pp. 585-626.

Ruberte, E., Friederich, V., Chambon, P. & Morriss-Kay, G. (1993) Retinoic acid receptors and cellular retinoid binding proteins. III. Their differential transcript distribution during mouse nervous system development. *Development*, **118**, 267-282.

Shaw, G.M., Lammer, E.J., Wasserman, C.R., O'Malley, C.D. & Tolarova, M.M. (1995) Risks of orofacial clefts in children born to women using multivitamins containing folic acid periconceptionally. *Lancet*, **346**, 393-396.

Shenefelt, R.E. (1972) Morphogenesis of malformations in hamsters caused by retinoic acid: relation to dose and stage at treatment. *Teratology*, **5**, 103-118.

Sulik, K.K., Johnston, M.C., Smiley, S.J., Speight, H.S. & Jarvis, B.E. (1987) Mandibulofacial dysostosis (Treacher Collins syndrome): a new proposal for its pathogenesis. *Am. J. Med. Genet.*, **27**, 359-372.

Tomo, S., Ogita, M. & Tomo, I. (1997) Development of mandibular cartilages in the rat. *Anat. Rec.*, **249**, 233-239.

Wagner, E., McCaffery, P. & Drager, U.C. (2000) Retinoic acid in the formation of the dorsoventral retina and its central projections. *Dev. Biol.,* **222**, 460-470.

Ward, S.J. & Morriss-Kay, G. (1997) The functional basis of tissue-specific retinoic acid signalling in embryos. *Semin. Cell Dev. Biol.*, **8**, 429-435.

Wilkinson, W.B. & Poswillo, D.E. (1991) Asymmetry in mandibulofacial dysostosis. *J. Craniofac. Genet. Dev. Biol.*, **11**, 41-47.

World Health Organization (2001) Report of a WHO registry meeting on craniofacial anomalies. In: *Global Registry and Database on Craniofacial Anomalies* edited by P. Mosey, and E. Castilla, WHO Registry Meeting on Craniofacial Anomalies, Baru, Brazil, pp. 26.

Underhill, T.M. & Weston, A.D. (1998) Retinoids and their receptors in skeletal development. *Microsc. Res. Tech.*, **43**, 137-155.

Yu, J., Gonzalez, S., Martinez, L., Diez-Pardo, J.A. & Tovar, J.A. (2003) Effects of retinoic acid on the neural crest-controlled organs of fetal rats. *Pediatr. Surg. Int.,* **19**, 355-358.