

Aural Myiasis in Children and Literature Review

KÖKSAL YUCA, HÜSEYİN ÇAKSEN,¹ YUNUS FEYYAT SAKİN, SEVİL ARI YUCA,³
MUZAFFER KIRIŞ, HASAN YILMAZ² and HAKAN ÇANKAYA

Department of Otorhinolaryngology, ¹ Department of Pediatrics, ² Department of Parasitology, Yüzüncü Yıl University Faculty of Medicine, Van, and ³ Women and Child Diseases Hospital, Van, Turkey

YUCA, K., ÇAKSEN, H., SAKİN, Y.F., YUCA, S.A., KIRIŞ, M., YILMAZ, H. and ÇANKAYA, H. *Aural Myiasis in Children and Literature Review*. Tohoku J. Exp. Med., 2005, **206** (2), 125-130 — Myiasis is a disease caused by fly larvae. The term “myiasis” is derived from the Greek word “myia” meaning fly. Aural myiasis is a rare clinical state and occurs frequently in children. In this article, six children with aural myiasis, caused by the fly larvae, are reported because of unusual presentation. All of the children with aural myiasis were associated with chronic otitis media. In the treatment, a combination of suctioning and alligator forceps was used to remove maggots under the light microscopic field. Additionally, antibiotics were used in all children. Thus, aural myiasis is successfully treated by direct extraction of larvae and application of preventative methods. ——— myiasis; fly larvae; chronic otitis media; maggots; children

© 2005 Tohoku University Medical Press

The term “myiasis” is derived from the Greek word “myia” meaning fly was coined in 1840. It was defined as the infestation of live human and vertebrate animals with dipterous larvae, which at least for a certain period feed on the host’s dead or living tissue, liquid body substances or ingested food (Bhatt and Jayakrishnan 2000).

Myiasis, the invasion of live mammalian tissue by larvae of dipteran flies to feed on the host’s organs, body fluids, or ingested food, may be specific, semispecific, or accidental. It is believed that the fly may even drop its eggs in flight on the skin, wounds, or natural openings of an immobile person. Myiasis-producing larvae attack three main parts of the body: cutaneous tissue (furuncular and creeping), body cavities, and body organs (Noutsis and Millikan 1994; Ciftcioglu et al.

1997).

The extent of disease and the host immune response depend on the fly species involved, the host (e.g., species, welfare and concomitant disease) and on the rearing conditions (e.g., environment and breeding management). Blowflies (*Calliphoridae*) and flesh flies (*Sarcophagidae*) cause myiasis of relatively short duration, by both obligate and/or facultative parasites, which mature within 4-7 days, usually at the host’s body orifices and in wounds (e.g., *Lucilia cuprina*, *Lucilia sericata*, *Cochliomyia hominivorax*, *Wohlfahrtia magnifica*, and *Chrysomya bezziana*) (Otranto 2001). Recently described human infestations have involved the nasotrachea, the eye, the mouth, the brain, the ear, the scalp, the penis, and the gums (Shah and Dayal 1984; Tomita et al. 1984; Arbit et al. 1986; Anil et al. 1989;

Received January 10, 2005; revision accepted for publication March 15, 2005.

Correspondence: Köksal Yuca, M.D., Yüzüncü Yıl University, Faculty of Medicine, Department of Otorhinolaryngology, 65200 Van, Turkey.

e-mail: koksalyuca@yahoo.com or koksalyuca@hotmail.com

Kalelioglu et al. 1989; Chodosh and Clarridge 1992; Josephson and Kraiden 1993; Ciftcioglu et al. 1997; Caca et al. 2003). Myiasis in humans may be benign to asymptomatic or may result in mild to violent disturbances, even death (Caca et al. 2003). Infestations of the nose and ears are extremely dangerous because of the possibility of penetration into the brain; the fatality rate is approximately 8% in such cases. Myiasis is not an uncommon parasitic infestation in the tropics and subtropics, and, due to international travel, cases are also encountered outside the endemic regions in both Europe and North America (Noutsis and Millikan 1994).

Aural myiasis is a rare clinical state and occurs frequently in children. It is also frequently seen in adults especially those who are mentally retarded. Most of the identified causative agents belong to the Sarcophagidae family. Among the Sarcophagidae species, *Wohlfahrtia magnifica* is frequently seen as a causative agent of various types of myiasis in the Mediterranean Basin, Southern Russia, Turkey, Israel and the Middle and Far East (Uzun et al. 2004; Hall and Wall 1995).

Myiasis can be classified depending on the condition of the involved tissue, into: accidental myiasis when larvae ingested along with food produce infection, semi-specific myiasis where the larvae are laid on necrotic tissue in wounds, and obligatory myiasis in which larvae affect undamaged skin. Based on the anatomic sites affected myiasis is subdivided into cutaneous myiasis, myiasis of external orifices (aural, ocular, nasal, oral, vaginal and anal), and myiasis of internal organs (intestinal and urinary) (Bhatt and Jayakrishnan 2000).

Herein, we present six children with aural myiasis, caused by the fly larvae (*Wohlfahrtia magnifica*) because of unusual presentation.

MATERIALS AND METHODS

The study included six pediatric patients (three females, and three males; mean age 4.9 years; range from 2 to 7 years) with aural myiasis, caused by the fly larvae (*Wohlfahrtia magnifica*). All cases were treated in Yüzüncü Yıl University Faculty of Medicine, Department

of Otorhinolaryngology between 2002 and 2004. The patients' data was retrospectively investigated based on their medical records. The study was approved by the ethics committee of our university hospital.

RESULTS

The patients were admitted to our department with the complaint of discharging ear, otalgia, or itching on the external auditory canal. In

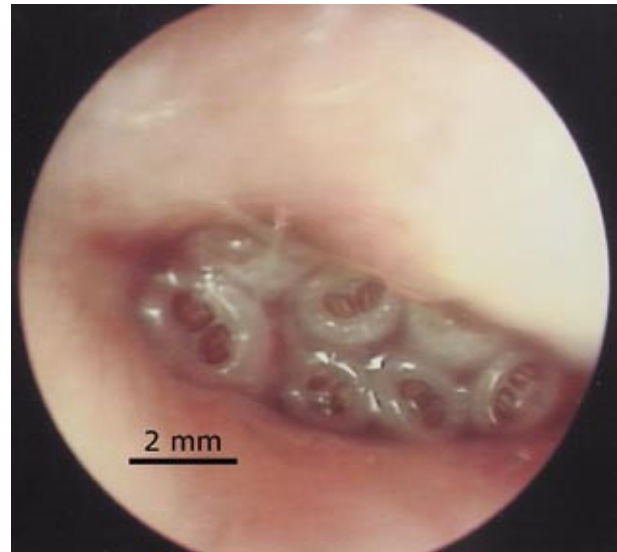


Fig. 1. Live maggots. Fly larvae in the external auditory canal by microscopic examination (scale bar: 2 mm).

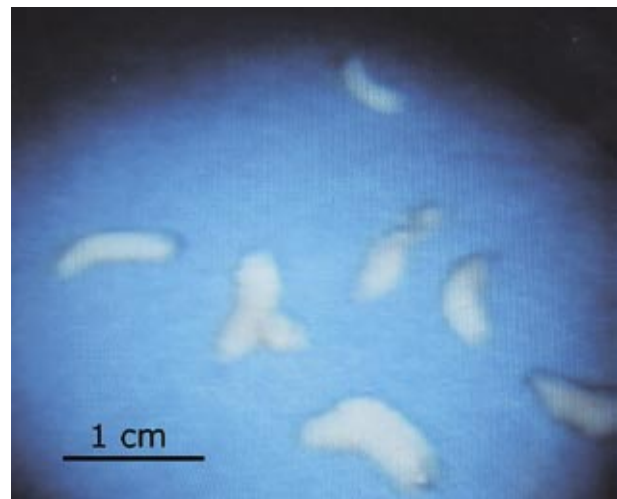


Fig. 2. Live maggots. Gross appearance of the removed live maggots (scale bar: 1 cm).

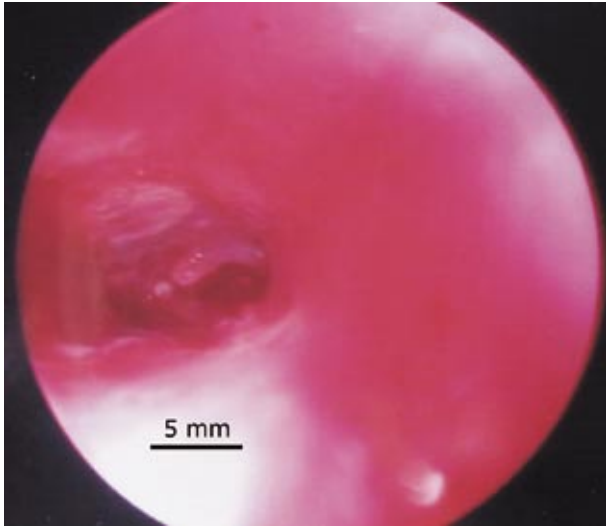


Fig. 3. Perforated tympanic membrane. Following removal of the maggots, the external auditory canal is clear (scale bar: 5 mm).

all of the children, otoscopic and microscopic examination revealed live maggots on the external auditory canal. Fig. 1 shows fly larvae in the ex-

ternal auditory canal. Fig. 2 appears gross appearance of the removed live maggots. All children with myiasis had perforated tympanic membrane and chronic otitis media with purulent discharge. Fig. 3 demonstrates perforated tympanic membrane after removal of the maggots.

Myiasis was diagnosed bilaterally in two (33%) of six children. Additionally, dead flies were extracted from external auditory canal in three (50%) children. Maggots were removed under the light microscopy (Carl Zeiss S21, OPMI 1-FC, Germany) with a combination of suctioning and alligator forceps. Only one patient required general anesthesia to remove of the aural myiasis. Additionally, topically and oral antibiotics were used in all children. Saline irrigation and concomitant suction were performed in all cases. During follow up of the cases, no symptom or sign of myiasis was noted. The clinical symptoms and features of the patients are summarized in Tables 1 and 2.

TABLE 1. *Symptoms of the patients*

Symptoms	Case (n)	%
Maggot in the EAC	6	100
Purulent secretion in the EAC	6	100
Aural malodor	5	83.3
Hemorrhagic secretion in the EAC	3	50
Otalgia	3	50
Aural itching	2	33.3

EAC, External auditory canal.

TABLE 2. *Clinical characteristic of the patients*

Case no	Sex	Age (years)	Localization	Duration between beginning of purulent secretion and admittance to hospital
1	Female	6	Left	1 year
2	Female	5	Left + Right	8 months
3	Male	2	Right	6 months
4	Female	7	Right	1 month
5	Male	6	Left	2 years
6	Male	3.5	Left + Right	3 months

DISCUSSION

Foreign bodies of the ears are a common and challenging problem in children (Baker 1987; Mishra et al. 2000; Yuca et al. 2003). Both live and non-vegetative, inanimate foreign bodies are encountered in external auditory canals in children (Yuca et al. 2003).

The aural myiasis is not a common infestation. Although it is not a common manifestation in the field of otorhinolaryngology, the possibility of its occurrence always exists. The clinical spectrum is wide from maggots in the ear to otalgia, otorrhea, perforation of drum, bleeding, itching, roaring sound, tinnitus, furuncle of the external ear, and restlessness (Cho et al. 1999). In the series of Singh and Rana (1993) the main symptoms in aural myiasis were passage of worms (81.48%), discharge (44.44%), and pain (41.97%). In our series the symptoms were in order as follows; purulent secretion in external auditory canal (100%), aural malodor (83.3%), hemorrhagic secretion in the external auditory canal (50%), otalgia (50%), and aural itching (33.3%).

A critical phase in the life cycle of the fly species that cause myiasis is host location by the adult females, whether by direct location of and contact with the host, or by indirect location through the selection of sites frequented by hosts. Fly larvae, or maggots, can be used to clean necrotic debris from a wound. Although it is repulsive, this may be effective. Some larvae are obligatory parasites of warm-blooded animals and sometimes of man. These must burrow into the flesh in order to develop (Elgart 1990).

Myiasis of the otolaryngological cavity usually occurs from neglected chronic lesions (such as neglected chronic suppurative otitis media) of the patients with poor personal hygiene (Uzun et al. 2004). In cases with aural myiasis, maggots are deposited in the human external ear and usually penetrate into the aural cavity. The injury of the auditory meatus may lead to deafness, meningitis or even death may occur (Uzun et al. 2004). In our series, the otomicroscopic examination of the cavity revealed that none of the cases had the evidence of surrounding tissue destruction.

Additionally, none of the cases revealed deafness or meningitis.

Bloody tinged discharge, tinnitus, bleeding, pain, and foul smelling discharge are reported symptoms. Aural myiasis is easily detectable by otoscopic examination (Cho et al. 1999). In our series, otoscopic and microscopic examination was performed in all of the children and live maggots on the external auditory canal were diagnosed.

If there is a perforation of the tympanic membrane and hearing loss, the examination of auditory function before and after treatment will be necessary. If it is not treated appropriately, the chronic inflammation of the external auditory canal, chronic otitis media or bony destruction from chronic suppuration may be developed (Cho et al. 1999). In our series, auditory function was not examined by audiogram because all are children. Instead, they were closely followed for chronic otitis media.

The majority of cases of human myiasis involve fly species that are facultative parasites; humans represent only a target of opportunity, presented through neglected wounds or lack of sanitary measures. The pathophysiology of myiasis was ignored until the discovery that the accidental myiasis of traumatic wartime wounds was associated with the production of healthy granulation tissue. These wounds appeared to heal more quickly and were associated with fewer bacterial infections than those wounds that were free of maggot infestation. Since maggots leave their host when they are fully mature and bury themselves in the soil, even infestations with obligate parasites usually cause only self-limited diseases. However, larvae may burrow into and destroy the tissue. Rapid destruction of adjacent tissues, including the bone, may result in the death of the host. Tissue destruction may occur by mechanical means and by the production of collagenase (Ciftcioglu et al. 1997). In our series, all of the children had purulent chronic otitis media for a long time, between one month and 2 years. We thought that aural myiasis was secondarily occurred to chronic otitis media.

Identification of the species of maggot prior

to the recommendation of treatment is important because not all types of myiasis are benign (Singh and Rana 1989). The pathogenesis depends on the species of fly involved and the location of the larvae. In humans, *Wohlfahrtia magnifica* larvae are often deposited into the ear, where they usually penetrate into the walls, and in rare cases, they enter the cartilage. The injury of the auditory meatus may lead to deafness. Cases of infestation of the eye are also common and may result in complete destruction of the eyeball. The nasal cavities may also become infected, and any kind of wound on any part of the body may attract the flies for larviposition. Fatal cases in humans have been reported (Ciftcioglu et al. 1997). Several cases of myiasis with skin, eye and radical mastoidectomy cavity involvement by *Wohlfahrtia magnifica* have been reported in Turkey (Ketene et al. 1993; Ciftcioglu et al. 1997; Uzun et al. 2004). Myiasis may also be accompanied by marked inflammatory reactions and secondary bacterial infections, massive destruction and life-threatening consequences such as intracranial invasion (Caca et al. 2003). In our series, all children with myiasis had perforated tympanic membrane and chronic otitis media with purulent discharge, but no intracranial invasion.

In a series of cutaneous myiasis, the immediate predisposing factor for dermatology patients was infected dermatitis. Other associated factors included diabetes mellitus, psychiatric illness, leprosy, and mental subnormality (Ng et al. 2003). None of our cases had diabetes mellitus, psychiatric illness, leprosy, and mental subnormality. However, all of the cases were ignored by their parents because of poor socioeconomic conditions.

The treatment of aural myiasis is simple in early manifestation stage, such as removal of maggots and cleaning lesion with 70% ethanol, 10% chloroform, oil drops, urea, dextrose, creatine, topical ivermectine and iodine saline or normal saline. However, they have controversial results. Prophylactic antibiotic therapy may prevent secondary infections (Cho et al. 1999; Uzun et al. 2004; Shinohara et al. 2004). If the tympanic membrane is perforated, cleaning with normal

saline and concomitant suction will be appropriate (Cho et al. 1999). In the series of Singh et al. (1993) consisting 94 cases of childhood myiasis 81 (86.16%) were of aural, 11 (11.7%) of nasal and two (2.12%) of ocular myiasis. All patients were treated with chloroform and turpentine oil in the ratio of 1:4, which was followed by manual removal of the maggots (Singh et al. 1993). In accordance with the literature, normal saline irrigation and concomitant suction were performed in all cases and antibiotics were given.

In conclusion, to reduce the incidence of these infestations, preventative measures (e.g., control of the fly populations, general cleaning such as reduction of odors of decomposition, the use of screens, and the cleaning and covering of wounds) should be applied. If the tympanic membrane is perforated in aural myiasis cases, concomitant suction and antibiotic therapy will be appropriate.

References

- Anil, S., Jacob, O.A. & Hari, S. (1989) Oral myiasis: a case report. *Ann. Dent.*, **48**, 28-30.
- Arbit, E., Varon, R.E. & Bre, S.S. (1986) Myiatic scalp and skull infection with diptera Sarcophaga: case report. *Neurosurgery*, **18**, 361-362.
- Baker, M.D. (1987) Foreign bodies of the ears and nose in childhood. *Pediatr. Emerg. Care*, **3**, 67-70.
- Bhatt, A.P. & Jayakrishnan, A. (2000) Oral myiasis: a case report. *Int. J. Paediatr. Dent.*, **10**, 67-70.
- Caca, I., Unlu, K., Cakmak, S.S., Bilek, K., Sakalar, Y.B. & Unlu, G. (2003) Orbital myiasis: case report. *Jpn. J. Ophthalmol.*, **47**, 412-414.
- Ciftcioglu, N., Altintas, K. & Haberal, M. (1997) A case of human orotracheal myiasis caused by *Wohlfahrtia magnifica*. *Parasitol. Res.*, **83**, 34-36.
- Cho, J.H., Kim, H.B., Cho, C.S., Huh, S. & Ree, H.I. (1999) An aural myiasis case in a 54-year-old male farmer in Korea. *Korean J. Parasitol.*, **37**, 51-53.
- Chodosh, J. & Clarridge, J. (1992) Ophthalmomyiasis: a review with special reference to *Cochliomyia hominivorax*. *Clin. Infect. Dis.*, **14**, 444-449.
- Elgart, M.L. (1990) Flies and myiasis. *Dermatol. Clin.*, **8**, 237-244.
- Hall, M. & Wall, R. (1995) Myiasis of humans and domestic animals. *Adv. Parasitol.*, **35**, 258-334.
- Josephson, R.L. & Kraiden, S. (1993) An unusual nosocomial infection: nasotracheal myiasis. *J. Otolaryngol.*, **22**, 46-47.
- Kalelioglu, M., Akturk, G., Akturk, F., Komsuoglu, S.S., Kuzeyli, K., Tigin, Y., Karaer, Z. & Bingol, R. (1989) Intracerebral myiasis from *Hypoderma bovis* larva in a child. *J. Neurosurg.*, **71**, 929-931.
- Ketene, M., Kutlu, N., Yormuk, E. & Altintas, K. (1993) Bir *Wohlfahrtia magnifica* myiasisi olgusu. *Turk. Plast. Cerrahisi Derg.*, **1**, 151-153.

- Mishra, A., Shukla, G.K. & Bhatia, N. (2000) Aural foreign bodies. *Indian J. Pediatr.*, **67**, 267-269.
- Ng, K.H., Yip, K.T., Choi, C.H., Yeung, K.H., Auyeung, T.W., Tsang, A.C., Chow, L. & Que, T.L. (2003) A case of oral myiasis due to *Chrysomya bezziana*. *Hong Kong Med. J.*, **9**, 454-456.
- Noutsis, C. & Millikan, L.E. (1994) Myiasis. *Dermatol. Clin.*, **12**, 729-736.
- Otranto, D. (2001) The immunology of myiasis: parasite survival and host defense strategies. *Trends Parasitol.*, **17**, 176-182.
- Shah, H.A. & Dayal, P.K. (1984) Dental myiasis. *J. Oral Med.*, **39**, 210-211.
- Shinohara, E.H., Martini, M.Z., Oliveira, Neto, H.G. & Takahashi, A. (2004) Oral myiasis treated with ivermectin: case report. *Braz. Dent. J.*, **15**, 79-81.
- Singh, I., Gathwala, G., Yadav, S.P., Wig, U. & Jakhar, K.K. (1993) Myiasis in children: the Indian perspective. *Int. J. Pediatr. Otorhinolaryngol.*, **25**, 127-131.
- Singh, T.S. & Rana, D. (1989) Urogenital myiasis caused by *Megaselia scalaris* (Diptera: phoridae): case report. *J. Med. Entomol.*, **26**, 228-229.
- Tomita, M., Uchijima, Y., Okada, K. & Yamaguchi, N. (1984) A report of self-amputation of the penis with subsequent complication of myiasis. *Hinyokika Kyo.*, **30**, 1293-1296.
- Uzun, L., Cinar, F., Beder, L.B., Aslan, T. & Altintas, K. (2004) Radical mastoidectomy cavity myiasis caused by *Wohlfahrtia magnifica*. *J. Laryngol. Otol.*, **118**, 54-56.
- Yuca, K., Yuca, S.A. & Caksen, H. (2003) Aural live foreign bodies in children. *J. Emerg. Med.*, **25**, 102-104.
-