

Successful Management of Gorham-Stout Disease in the Cervical Spine by Combined Conservative and Surgical Treatments: A Case Report

Satoshi Tateda,¹ Toshimi Aizawa,² Ko Hashimoto,² Haruo Kanno,² Susumu Ohtsu,³ Eiji Itoi² and Hiroshi Ozawa¹

¹Department of Orthopaedic Surgery, Tohoku Medical and Pharmaceutical University, Sendai, Miyagi, Japan

²Department of Orthopaedic Surgery, Tohoku University School of Medicine, Sendai, Miyagi, Japan

³Department of Orthopaedic Surgery, Osaki Citizen Hospital, Osaki, Miyagi, Japan

Gorham-Stout disease (GSD) is a rare condition characterized by intraosseous proliferation of endothelial-lined vessels and progressive osteolysis. The precise etiology and pathophysiology of the disease remain poorly understood. Current therapeutic options for GSD include chemotherapy, radiotherapy, and surgical resection, but the surgical treatment of GSD is difficult, especially in the spinal lesion. The indication of wide-margined resection was limited because of anatomical features. Herein, we report a case of GSD of the cervical spine in which the lesions were successfully stabilized with combined conservative and surgical treatments. A 15-year-old male patient was admitted because of severe neck pain. The patient presented no neurological deficiency. However, the radiological findings revealed osteolytic lesions on the laminae and vertebrae between C1 to C5. An open biopsy confirmed an irregular, thin-walled vessel formation in the bone trabeculae, which was diagnosed as GSD. Conservative treatment was initiated with chemotherapy and radiotherapy. After one and a half year, the osteolytic condition had regressed. Spinal fusion surgery was then performed from C2 to C5 to prevent for progression of the cervical kyphotic changes, and spinal fusion was confirmed 7 months after the surgery. The patient showed no recurrence of GSD in the 5-year follow-up period after surgery. We were able to provide successful treatment by giving priority to the combined conservative treatments. If a patient has no severe deformity or progressive neurologic deficits, it might be better to prioritize conservative treatments and to perform the surgery after the osteolytic changes have stopped.

Keywords: anterior spinal fusion; atlanto-axial rotatory fixation; cervical spine; conservative treatment; Gorham-Stout disease

Tohoku J. Exp. Med., 2017 April, **241** (4), 249-254. © 2017 Tohoku University Medical Press

Introduction

Gorham-Stout disease (GSD) is a rare condition characterized by intraosseous proliferation of endothelial-lined vessels and progressive osteolysis (Gorham and Stout 1955). The precise etiology and pathophysiology of the disease remain poorly understood (Lehmann et al. 2009; Dellinger et al. 2014). Furthermore, due to uncertainty about the underlying cause, the appropriate treatment and prognosis currently remain uncertain. Therapeutic options for GSD include chemotherapy, radiotherapy, and surgical resection, and early, complete recover can be achieved only by wide-margined resection such as amputation and endoprosthesis replacement. If the resection is incomplete, osteolysis can reoccur in the remained regions. In the spinal lesion, total spondylectomy might be recommended for

GSD in the thoracic or lumbar level that involve a small number of vertebrae since this procedure can completely remove the osteolytic lesions (Chong Ng and Sell 2003; Aizawa et al. 2005). However, it is difficult to resect the vertebral column totally if a large number of vertebrae or the cervical spine is affected because of the anatomical and technical problems. Determining the timing of surgical interventions is also difficult in the cases, in which total spondylectomy cannot be performed, as the grafted bone should be resorbed if it were performed before disease regression. Here, we report a patient with GSD of the cervical spine in which the lesions were successfully stabilized with combined conservative and surgical treatments. We present our therapeutic strategy for GSD in the spinal lesion.

Received November 28, 2016; revised and accepted March 10, 2017. Published online March 29, 2017; doi: 10.1620/tjem.241.249.

Correspondence: Toshimi Aizawa, M.D., Ph.D., Department of Orthopaedic Surgery, Tohoku University School of Medicine, 1-1 Seiryomachi, Aoba-ku, Sendai, Miyagi 980-8574, Japan.
e-mail: toshi-7@ra2.so-net.ne.jp

Case Report

A 15-year-old male patient complaining of neck pain with restricted neck motion was admitted to Tohoku University Hospital. Radiologically, massive osteolytic lesions were confirmed from C1 to C5, particularly in the laminae and the spinous processes (Fig. 1). On the magnetic resonance imaging (MRI), these lesions showed a low signal intensity on T1-weighted images (T1WIs), a heterogeneously high signal intensity on T2WIs, and slight enhancement by gadolinium-diethylenetriaminepentaacetic acid (Gd-DTPA) (Fig. 2). A plain chest radiograph revealed pleural effusion, which was diagnosed as chylothorax and was successfully treated by chemical pleurodesis with plicabril (Noda et al. 2013). The blood examination indicated almost normal except for a high value of cross-linked

N-terminal telopeptides of type I collagen (59.9 nmol/L). An open biopsy was performed from the C2 spinous process. The histology revealed many irregular ectatic vasculars among the thin bone trabeculae, woven bone, osteoid formation, and an area with a large amount of osteoclasts. There were no malignant cells in the tissue (Fig. 3). The histologic diagnosis was GSD. Chemotherapy was started using interferon α -2b (1,000,000-4,000,000 units/day) and pamidronate disodium (30 mg/week) and was continued for about one and a half years, until the osteolytic condition regressed.

About one month after admission, the patient noticed severer neck pain and more restriction of his neck motion, with a cock robin deformity. CT revealed atlanto-axial rotatory fixation (AARF) and progression of osteolysis of the dens and posterior part of the C2 to C5 (Fig. 4). AARF

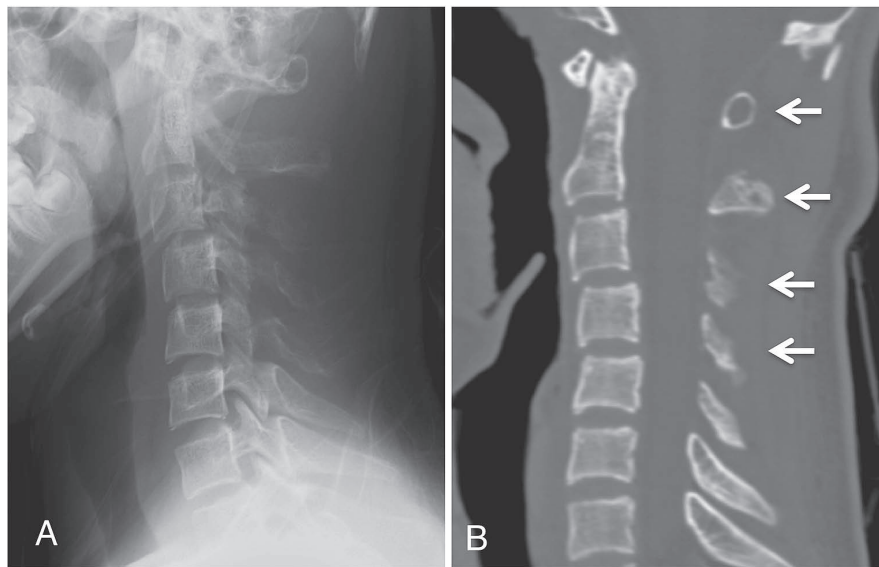


Fig. 1. Plain radiograph and computed tomography (CT) of the cervical spine on admission. Osteolytic changes were observed in the vertebral bodies, laminae, and spinous processes from C1 to C5. The cortical bone was thinned and small radiolucent foci were observed in the spinal bone (arrows) (A: plain lateral radiograph; B: sagittal reconstructed CT).

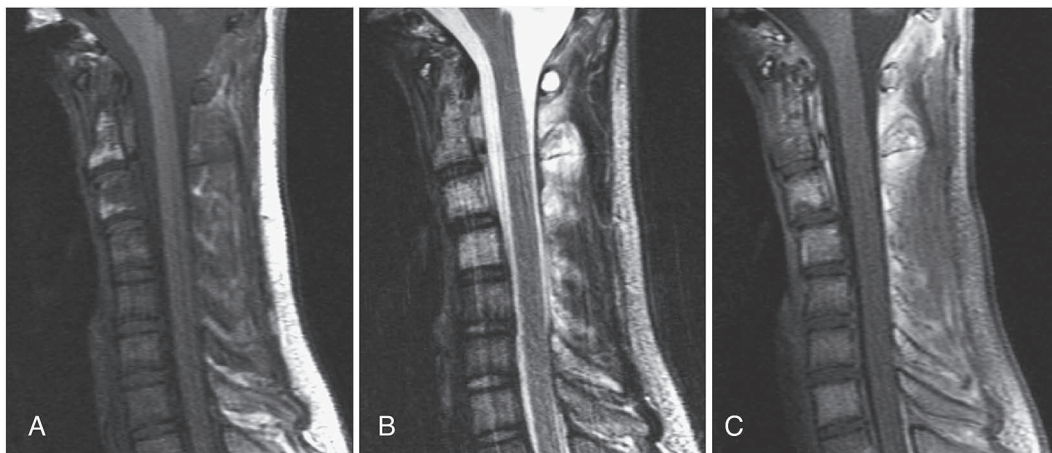


Fig. 2. Magnetic resonance imaging (MRI) of the cervical spine on admission. The vertebral bodies, laminae, and spinous processes from C1 to C5 showed a low signal intensity on T1-weighted images and a heterogeneously high signal intensity on T2-weighted images (A, B). They were slightly enhanced by Gd-DTPA (C).

was not reduced manipulatively and gradually reduced by a halo-ring traction, which was stabilized by a halo vest. The halo vest was continued to use 18 months before surgery, and 4 months after surgery until the bony union from C2 to C5 was confirmed. We applied 36 Gy radiotherapy in the expectation of the disease activity to regress 6 months after admission.

CT at one year after radiotherapy showed no progression of osteolysis. Furthermore, MRIs revealed that the affected vertebrae had turned into a homogenously high signal intensity on both the T1WIs and T2WIs, with no significant Gd enhancement, which suggested that the lesions were fatty bone marrow (Fig. 5). We considered that the osteolytic condition had regressed, or at least stabilized.

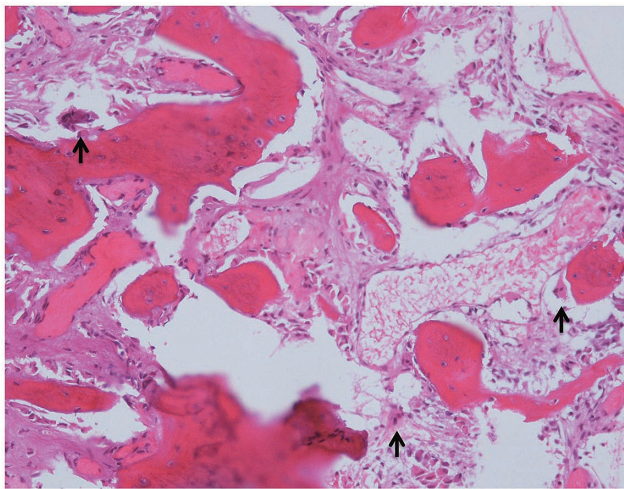


Fig. 3. Histology of the specimen. Irregular, thin-walled vessel formation was detected in the bone trabeculae. No malignant cells were observed. A couple of osteoclasts were also observed (arrows).

However, since the osteolytic change in the posterior part of the spine resulted in cervical kyphosis, we planned spinal fusion from C2 to C5 to prevent further progression of kyphotic change. The anatomy of posterior part of spine was predicted to be abnormal; the spinous processes were almost disappeared, and the pedicles and laminae were very thin. Therefore, we performed instrumented anterior spinal fusion with iliac bone graft and screw and plate system. CT at 7 months after surgery revealed complete bony union from C2 to C5 (Fig. 6). The patient was discharged from our hospital 2 years and 2 months after admission. He showed no recurrence of GSD without additional treatment in the 5-year follow-up period after surgery.

The patient and his family were informed that the data from this case would be submitted for publication, and the patient provided his consent.

Discussion

GSD of the spine can cause severe symptoms, including neurological defects, deformity, and paralysis. In addition, anatomical features make treatment of the spinal vertebrae challenging on several accounts. Fifty-nine cases of spinal GSD have been reported in the English literature between 1947 and 2016. Table 1 presents a summary of these reports. Although GSD can occur at any spinal level, the cervical spine (49%) and thoracic spine (46%) were most frequently involved. In most cases, multiple vertebrae were involved. Twelve patients died, including seven from pulmonary disorders believed to be chylothoraces. Twenty-five cases presented some kind of paralysis; in particular, those with lower cervical to thoracic lesions demonstrated severe kyphosis leading to severe paralysis. Twenty-eight cases were treated surgically as they showed neurological deterioration and/or progressive kyphosis. However, due to

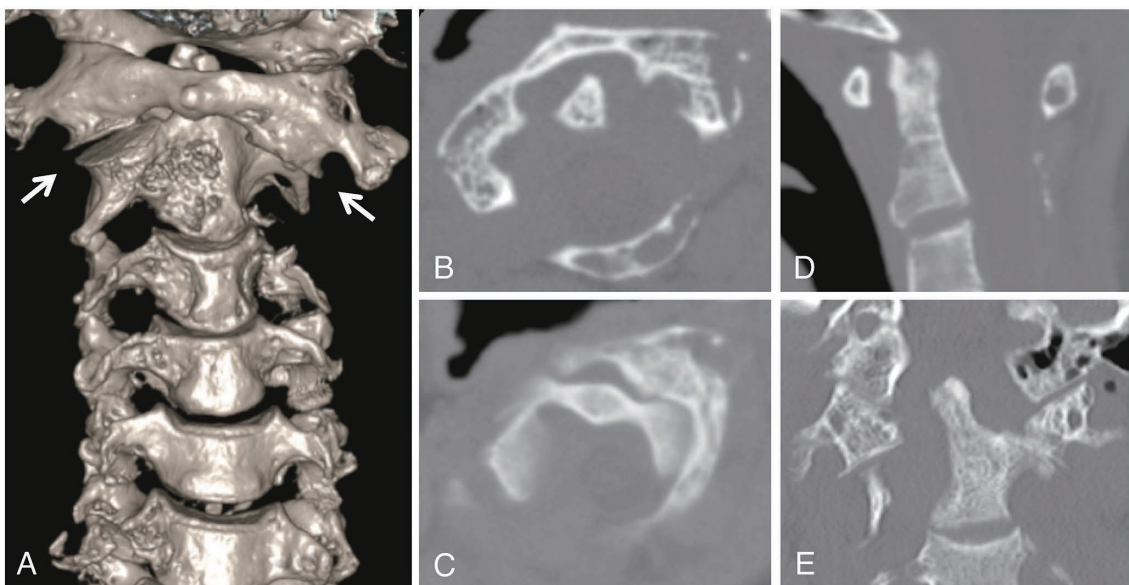


Fig. 4. 3D-CT and axial plane images of the upper cervical spine one month after admission. Osteolytic changes were in progress in the C1 lateral mass, the dens, and the posterior part of C2 to C5, and the atlanto-axial joint showed a rotatory dislocation (arrows) (A: 3D-CT; B, C: axial planes; D: sagittal plane; E: coronal plane).

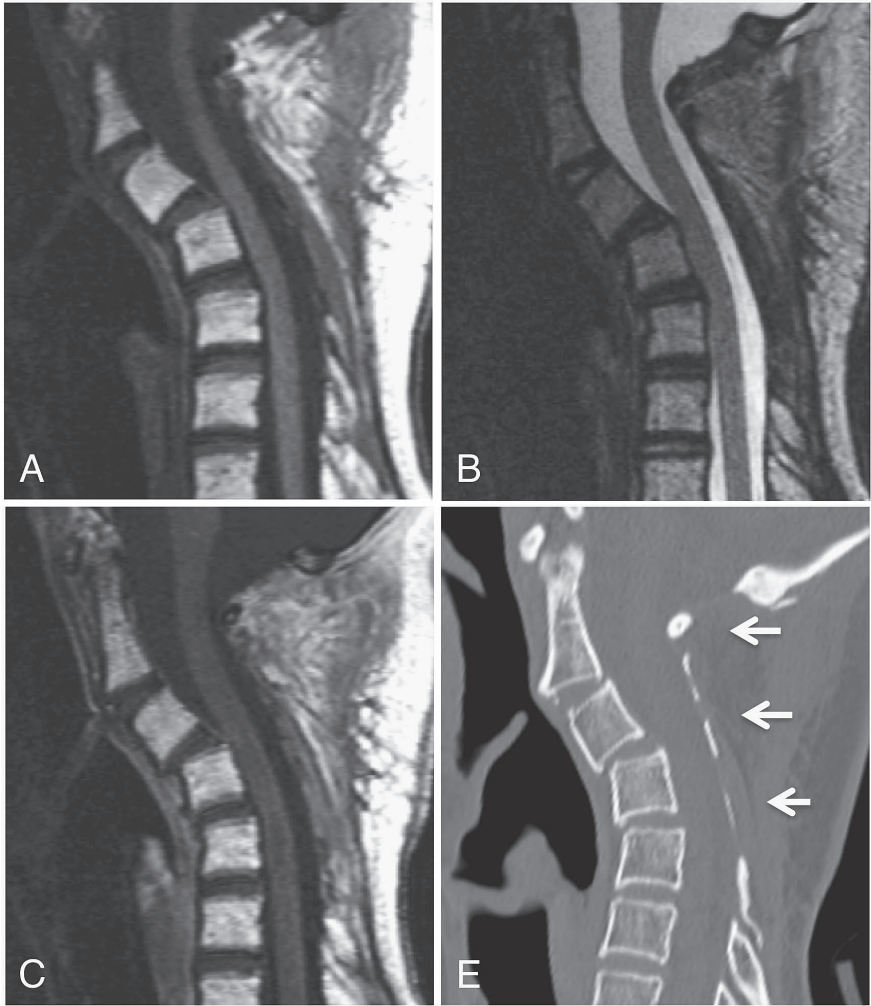


Fig. 5. MRI and CT of the cervical spine after radiation. Cervical kyphotic change was seen in C2-5. The involved vertebral bodies, laminae, and spinous processes showed homogeneous high signal intensity on both T1- and T2-weighted images (A, B). There were no significant enhanced lesions on Gd-DTPA (C). On CT, the cortical bone was clearly visualized, and the small radiolucent foci disappeared (arrows) (E).

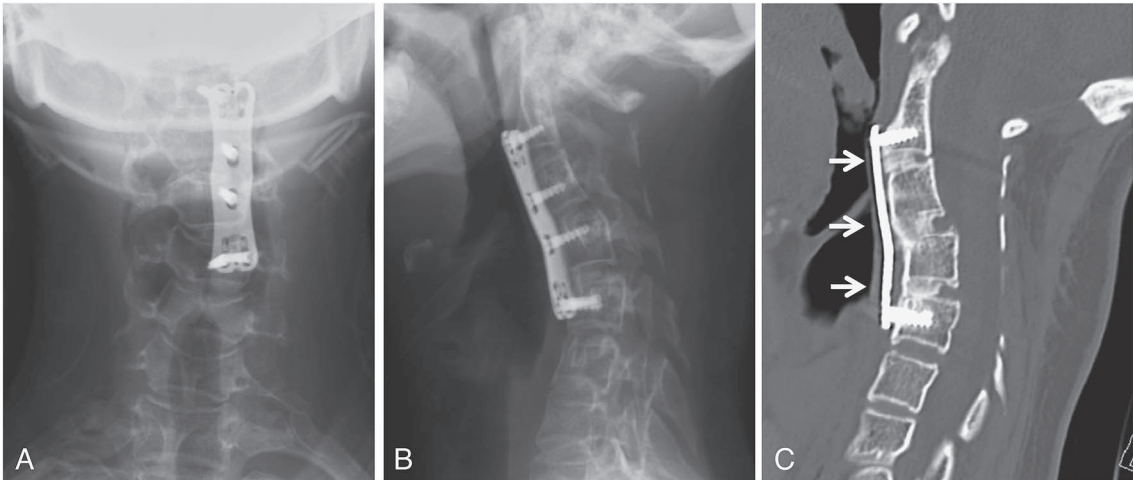


Fig. 6. Plain radiographs and CT of the cervical spine 7 months after surgery. Anterior spinal fusion was performed with plates and screws from C2 to C5 (A, B). Computed tomography showed complete bony union between C2 and C5 (arrows) (C).

Table 1. Summary of Gorham-Stout disease in spine (1947-2016).

Factors		Number of Patients (%)
Total number		
	mean age	27.4 (2–72)
		59 (100)
Sex		
	Male	38 (64)
	Female	21 (36)
Level of spine*		
	Cervical	29 (49)
	Thoracic	27 (46)
	Lumbar	17 (29)
	Sacral	5 (9)
Fatality Rate		
	Total	12 (20)
	Pulmonary disorder	7 (12)
Palarysis		
	Total	25 (42)
	Cervical or thoracic	24 (41)
Surgery		
	Total	27 (46)
	Completion by single operation	10 (17)
	Spondylectomy	5 (9)
	Multiple operation	13 (22)

*The lesions of several patients extended over two or three spinal levels.

resorption of the grafted bone, revision surgeries were frequently performed. Only 10 cases indicated control of the lesions with a single surgery, 5 of which involved spondylectomy (Halliday et al. 1964; Kai et al. 2006; Barman et al. 2013; Esmailieh et al. 2013; Kakuta et al. 2014).

Numerous treatments have been tested for GSD, including radiotherapy, chemotherapy, and surgery. The effectiveness of radiotherapy remains controversial. While some authors reported that it could not stop the progression of osteolysis (Chung et al. 1997; Bode-Lesniewska et al. 2002), others showed that it could control GSD effectively (Mawk et al. 1997; Heyd et al. 2011a). Heyd et al. reported a 77% to 80% success rate of radiotherapy, and recommended a total dose ranging from 36 to 45 Gy (Heyd et al. 2011a). As for chemotherapy, bisphosphonates (Lehmann et al. 2009) and interferon α -2b (Hagberg et al. 1997) have most commonly been used. Other pharmaceuticals, including the anti-VEGF-A antibody (Grunewald et al. 2010), propranolol (Nir et al. 2014), low molecular weight heparin (Brodzski et al. 2011), and rapamycin (Hammill et al. 2011), have also been tested experimentally. As pharmaceuticals have usually been used in combination with other therapeutic approaches, it has been difficult to assess their effect on the GSD accurately. Therefore, it is unclear which pharmaceutical agent is most effective. Some reports have indicated that the combination of radiotherapy and chemotherapy was effective (Hagberg et al. 1997; Heyd et al. 2011b). Those previous reports indicate that there is no gold standard treatment for this singular bone disease.

We proposed a treatment strategy for spinal GSD in our previous article (Aizawa et al. 2005): the present case was applying to those with the affected vertebrae show minor deformity with no neurologic deficits. Therefore, we performed conceivable conservative treatments in combined with chemotherapy and radiotherapy until the osteolytic changes should be considered as an arrest. The disease remission could be confirmed by the MRI findings: the disappearance of Gd enhancement and of fatty degeneration of the vertebral bodies, supported similar findings as in the previous report of arrested osteolytic changes (Manisali and Ozaksoy 1998). However, the osteolytic change in the posterior part of the spine resulted in cervical kyphosis. The muscle-tendon junction of the posterior part of the spine was disrupted, which means the posterior support system was destroyed. Spinal posterior support system, such as the supraspinal ligament, the interspinous ligament, and the paraspinal muscle play an important role in the supportability of the spinal column (Papagelopoulos et al. 1997). Progression of cervical kyphotic change was predicted due to destruction of these structures, so we added an instrumented spinal fusion surgery. We performed anterior surgery because: 1) this patient was 15 years old and the size of the pedicles were not large for pedicle screw insertion, 2) osteolytic change was dominant in the posterior elements of the spine, which indicated that screws through posterior approach such as pedicle screw and lateral mass screw should not be effective for rigid spinal fusion, and 3) the grafted bone might be osteolyzed on the laminae.

Fortunately, those treatments resulted in the complete remission of the GSD and bony fusion without osteolysis of the grafted bones.

The surgical treatment of GSD of the spine is difficult and the result has been mostly poor. We were able to provide successful treatment for this patient by giving priority to the combined conservative treatments. If a patient has no severe deformity or progressive neurologic deficits, it might be better to prioritize conservative treatments as long as possible, and to perform the surgery after the osteolytic changes have stopped similar as the present case. During the conservative treatment, the changes on the MRI, including the disappearance of Gd enhancement and of fatty degeneration of the vertebral bodies would be helpful in the evaluation of the disease activity.

Conflict of Interest

The authors declare no conflict of interest.

References

- Aizawa, T., Sato, T. & Kokubun, S. (2005) Gorham disease of the spine: a case report and treatment strategies for this enigmatic bone disease. *Tohoku J. Exp. Med.*, **205**, 187-196.
- Barman, A., Bhide, R., Viswanathan, A., George, J., Thomas, R. & Tharion, G. (2013) Gorham's disease of the spine. *NeuroRehabilitation*, **33**, 121-126.
- Bode-Lesniewska, B., von Hochstetter, A., Exner, G.U. & Hodler, J. (2002) Gorham-Stout disease of the shoulder girdle and cervico-thoracic spine: fatal course in a 65-year-old woman. *Skeletal Radiol.*, **31**, 724-729.
- Brodzki, N., Lansberg, J.K., Dictor, M., Gyllstedt, E., Ewers, S.B., Larsson, M.K. & Eklund, E.A. (2011) A novel treatment approach for paediatric Gorham-Stout syndrome with chylothorax. *Acta Paediatr.*, **100**, 1448-1453.
- Chong Ng, L. & Sell, P. (2003) Gorham disease of the cervical spine-a case report and review of the literature. *Spine*, **28**, E355-358.
- Chung, C., Yu, J.S., Resnick, D., Vaughan, L.M. & Haghighi, P. (1997) Gorham syndrome of the thorax and cervical spine: CT and MRI findings. *Skeletal Radiol.*, **26**, 55-59.
- Dellinger, M.T., Garg, N. & Olsen, B.R. (2014) Viewpoints on vessels and vanishing bones in Gorham-Stout disease. *Bone*, **63**, 47-52.
- Esmailieh, A.A., Kamalian, N. & Abbasian, M. (2013) Temporary paraplegia resulting from Gorham's disease involving the third lumbar vertebra and proximal femur: a five-year follow-up and review of the literature. *Arch. Iran. Med.*, **16**, 686-690.
- Gorham, L.W. & Stout, A.P. (1955) Massive osteolysis (acute spontaneous absorption of bone, phantom bone, disappearing bone): its relation to hemangiomatosis. *J. Bone Joint Surg.*, **37**, 985-1004.
- Grunewald, T.G., Damke, L., Maschan, M., Petrova, U., Surianinova, O., Esipenko, A., Kononov, D., Behrends, U., Schiessl, J., Wortler, K., Burdach, S. & von Luettichau, I. (2010) First report of effective and feasible treatment of multifocal lymphangiomatosis (Gorham-Stout) with bevacizumab in a child. *Ann. Oncol.*, **21**, 1733-1734.
- Hagberg, H., Lamberg, K. & Astrom, G. (1997) Alpha-2b interferon and oral clodronate for Gorham's disease. *Lancet*, **350**, 1822-1823.
- Halliday, D.R., Dahlin, D.C., Pugh, D.G. & Young, H.H. (1964) Massive osteolysis and angiomas. *Radiology*, **82**, 637-644.
- Hammill, A.M., Wentzel, M., Gupta, A., Nelson, S., Lucky, A., Elluru, R., Dasgupta, R., Azizkhan, R.G. & Adams, D.M. (2011) Sirolimus for the treatment of complicated vascular anomalies in children. *Pediatr. Blood Cancer*, **57**, 1018-1024.
- Heyd, R., Micke, O., Surholt, C., Berger, B., Martini, C., Fuller, J., Schimpke, T. & Seegenschmiedt, M.H. (2011a) Radiation therapy for Gorham-Stout syndrome: results of a national patterns-of-care study and literature review. *Int. J. Radiat. Oncol. Biol. Phys.*, **81**, e179-185.
- Heyd, R., Rabeneck, D., Dornenburg, O., Tselis, N. & Zamboglou, N. (2011b) Gorham-Stout syndrome of the pelvic girdle treated by radiation therapy: a case report. *Strahlenther. Onkol.*, **187**, 140-143.
- Kai, B., Ryan, A., Munk, P.L. & Dunlop, P. (2006) Gorham disease of bone: three cases and review of radiological features. *Clin. Radiol.*, **61**, 1058-1064.
- Kakuta, Y., Iizuka, H., Kobayashi, R., Iizuka, Y., Takahashi, T., Mohara, J. & Takagishi, K. (2014) Gorham disease of the lumbar spine with an abdominal aortic aneurysm: a case report. *Spine J.*, **14**, e5-9.
- Lehmann, G., Pfeil, A., Bottcher, J., Kaiser, W.A., Fuller, J., Hein, G. & Wolf, G. (2009) Benefit of a 17-year long-term bisphosphonate therapy in a patient with Gorham-Stout syndrome. *Arch. Orthop. Trauma Surg.*, **129**, 967-972.
- Manisali, M. & Ozaksoy, D. (1998) Gorham disease: correlation of MR findings with histopathologic changes. *Eur. Radiol.*, **8**, 1647-1650.
- Maw, J.R., Obukhov, S.K., Nichols, W.D., Wynne, T.D., Odell, J.M. & Urman, S.M. (1997) Successful conservative management of Gorham disease of the skull base and cervical spine. *Childs Nerv. Syst.*, **13**, 622-625.
- Nir, V., Guralnik, L., Livnat, G., Bar-Yoseph, R., Hakim, F., Ilivitzki, A. & Bentur, L. (2014) Propranolol as a treatment option in Gorham-Stout syndrome: a case report. *Pediatr. Pulmonol.*, **49**, 417-419.
- Noda, M., Endo, C., Hoshikawa, Y., Ishibashi, N., Suzuki, T., Okada, Y. & Kondo, T. (2013) Successful management of intractable chylothorax in Gorham-Stout disease by awake thoracoscopic surgery. *Gen. Thorac. Cardiovasc. Surg.*, **61**, 356-358.
- Papagelopoulos, P.J., Peterson, H.A., Ebersold, M.J., Emmanuel, P.R., Choudhury, S.N. & Quast, L.M. (1997) Spinal column deformity and instability after lumbar and thoracolumbar laminectomy for intraspinal tumors in children and young adults. *Spine*, **22**, 442-451.