



Preventive Effect of Tonsillectomy on Recurrence of Henoch-Schönlein Purpura Nephritis after Intravenous Methylprednisolone Pulse Therapy

Chisato Umeda,^{1,2} Shuichiro Fujinaga,¹ Amane Endo,³ Koji Sakuraya,^{1,3} Satoshi Asanuma⁴ and Daishi Hirano²

¹Division of Nephrology, Saitama Children's Medical Center, Saitama, Saitama, Japan

²Department of Pediatrics, The Jikei University School of Medicine, Tokyo, Japan

³Department of Pediatrics and Adolescent Medicine, Juntendo University School of Medicine, Tokyo, Japan

⁴Division of Otorhinolaryngology, Saitama Children's Medical Center, Saitama, Saitama, Japan

Henoch-Schönlein purpura (HSP) is regarded as a benign and self-limiting vasculitis characterized by purpura, arthritis, and gastrointestinal symptoms; however, about one third of the patients develop HSP nephritis (HSPN), the most serious long-term complication. Since 2013, we have proposed that tonsillectomy in addition to intravenous methylprednisolone pulse therapy (IVMP) be performed in all patients with HSPN, similar to immunoglobulin A nephropathy (IgAN) patients because both diseases are considered to share a common pathogenesis. Herein, we retrospectively reviewed the clinical courses of 71 Japanese children with HSPN (34 boys; median age at diagnosis, 6.7 years; median follow-up period, 5.6 years) who had received initial treatment with IVMP (15-20 mg/kg; on 3 consecutive days/week for 3 weeks) followed by oral prednisolone (initially 1 mg/kg; tapered off within 12 months) and achieved clinical remission (i.e., disappearance of both proteinuria and hematuria). The patients were divided into two groups: 31 patients receiving tonsillectomy after IVMP between 2013 and 2017 (tonsillectomy group) and 40 patients receiving IVMP monotherapy between 2003 and 2012 (IVMP group). For the 2 years after IVMP therapy, the rate of HSPN recurrence (i.e., persistent proteinuria combined with hematuria requiring additional treatments) after clinical remission was significantly lower in the tonsillectomy group than the IVMP group (0% vs. 19%, $P < 0.05$). Despite the short follow-up period in the tonsillectomy group, this study provides the evidence that tonsillectomy may be beneficial for preventing recurrence of HSPN from clinical remission with IVMP therapy in Japanese children.

Keywords: Henoch-Schönlein purpura nephritis; immunoglobulin A nephropathy; intravenous methylprednisolone pulse; recurrence; tonsillectomy

Tohoku J. Exp. Med., 2020 January, 250 (1), 61-69.

Introduction

Henoch-Schönlein purpura (HSP) is the most common vasculitis in childhood and is traditionally regarded as a benign and self-limiting disease characterized by purpura, arthritis, and gastrointestinal symptoms. However, approximately one third of patients develop HSP nephritis (HSPN), which is the most serious long-term complication of this type of vasculitis. HSPN patients with persistent proteinuria have a high risk of chronic kidney disease (CKD) progression, and 20% of these patients in tertiary centers progress

to end-stage kidney disease (ESKD) (Davin and Coppo 2014).

HSPN as well as Immunoglobulin A nephropathy (IgAN) is pathologically characterized by mesangial proliferative glomerulonephritis with the deposition of IgA immune complexes and various degrees of crescent formation. Although optimal treatment for childhood HSPN remains unclear, a prospective study showed that early treatment with intravenous methylprednisolone pulse (IVMP) therapy before the cellular crescents become fibrous may be effective for treating patients at risk of

Received November 20, 2019; revised and accepted January 16, 2020. Published online January 30, 2020; doi: 10.1620/tjem.250.61.

Correspondence: Shuichiro Fujinaga, M.D., Ph.D., Division of Nephrology, Saitama Children's Medical Center, 1-2 Shintoshin, Chuo-ku, Saitama, Saitama 330-8777, Japan.

e-mail: f_shuich@d2.dion.ne.jp

©2020 Tohoku University Medical Press. This is an open-access article distributed under the terms of the Creative Commons Attribution-NonCommercial-NoDerivatives 4.0 International License (CC-BY-NC-ND 4.0). Anyone may download, reuse, copy, reprint, or distribute the article without modifications or adaptations for non-profit purposes if they cite the original authors and source properly. <https://creativecommons.org/licenses/by-nc-nd/4.0/>

developing CKD (Niaudet and Habib 1998). We also reported the efficacy of early treatment with IVMP followed by oral prednisolone (PSL) in children with HSPN and heavy proteinuria (Fujinaga et al. 2012). Even with aggressive treatment, however, recurrence of HSPN after long-term remission developed in some patients (Fujinaga et al. 2006). Although persistent proteinuria after recurrence may be a major cause of unfavorable renal outcome, no information is available regarding the prevention of HSPN recurrence, especially in children.

Hotta et al. (2001) reported that tonsillectomy combined with IVMP followed by oral PSL was effective for achieving clinical remission (i.e., disappearance of both proteinuria and hematuria) in about half of IgAN patients. Furthermore, Ieiri et al. (2012) showed that the rate of clinical remission was significantly high (87.3%) in patients with shorter disease duration (< 36 months). Recently, a randomized controlled trial (RCT) in Japan demonstrated that tonsillectomy combined with IVMP was more effective than IVMP monotherapy in reducing urinary protein excretion after 1 year (Kawamura et al. 2014). On the other hand, in the European validation study of the Oxford classification of IgA nephropathy (VALIGA), no significant correlation was found between tonsillectomy and changes in proteinuria during the follow-up period (Feehally et al. 2016).

Several recent retrospective studies in Asian countries have shown that tonsillectomy is associated with reduction of not only urinary protein excretion but also the future recurrence of IgAN (Ohya et al. 2013; Hirano et al. 2016; Yang et al. 2016). As IgAN and HSPN are considered to share common pathological mechanisms (Rai et al. 1999), it may be reasonable to employ similar therapeutic approaches for both clinical entities. Although many reports have described the efficacy of tonsillectomy combined with IVMP in IgAN patients, there have been very few studies regarding such treatment strategies in children with HSPN (Inoue et al. 2007; Kawasaki et al. 2007; Kanai et al. 2011). In the present study, we investigated the prognosis of Japanese children with HSPN and persistent proteinuria who underwent tonsillectomy combined with IVMP therapy and compared their outcomes with those of patients who had previously received IVMP monotherapy without tonsillectomy at our hospital.

Patients and Methods

Patients

We retrospectively reviewed the records of 71 Japanese children (age < 18 years; median age, 6.7 years; 34 boys and 37 girls) with persistent proteinuria in newly biopsy-proven HSPN who were initially treated with IVMP followed by oral PSL at Saitama Children's Medical Center between February 2003 and May 2017 and followed up for at least 2 years. No patients had repeated episodes of tonsillitis before the diagnosis of HSPN in this study. Thirty-one patients had undergone tonsillectomy after IVMP ther-

apy since 2013 (tonsillectomy group), whereas 40 patients did not undergo tonsillectomy between 2003 and 2012 (IVMP group). The short-term clinical courses of 23 patients in the IVMP group have been published previously (Fujinaga et al. 2012). Renal biopsy was performed in all HSPN children with persistent proteinuria (early morning urinary protein-to-creatinine ratio: UP/C, ≥ 1.0 g/g for > 1 month, or 0.2-1.0 g/g for > 3 months) at our center. None of the patients had a history of treatment with IVMP or immunosuppressive agents. Children with a history of primary IgAN, systemic lupus erythematosus, or chronic liver diseases were also excluded. This study was approved by the Ethics Committee of Saitama Children's Medical Center (approval number 2019-03-002), and all patients and their parents provided informed consent.

Definitions

Hematuria was defined as urinary sediment containing ≥ 5 red blood cells (RBCs) per high-power field (hpf) on microscopic examination. Significant proteinuria and heavy proteinuria were defined as UP/C ≥ 0.2 and ≥ 1.0 g/g, respectively. Nephrotic syndrome was defined as the presence of hypoalbuminemia (≤ 2.5 g/dL) and UP/C ≥ 2.0 g/g. Clinical remission (CR) was defined as the disappearance of both hematuria and proteinuria, in two consecutive tests. Disappearance of proteinuria and hematuria was defined as UP/C < 0.2 g/g and RBC count < 5/hpf, respectively, in two consecutive tests. Recurrence was defined as the reappearance of persistent significant proteinuria combined with hematuria requiring additional treatments after it had initially disappeared with treatment. Hypertension was defined as systolic or diastolic blood pressure > 95th percentile for age (National High Blood Pressure Education Program Working Group on High Blood Pressure in Children and Adolescents 2004). The estimated glomerular filtration rate (eGFR) was calculated based on serum creatinine level and the patient's height (Uemura et al. 2014).

Renal biopsies were examined by a single pathologist and classified in accordance with the modified Oxford classification and the International Study of Kidney Disease in Children (ISKDC) scoring system. Based on the new Oxford Classification of IgAN (Trimarchi et al. 2017), MEST-C scores, which consist of M, mesangial hypercellularity; E, endocapillary proliferation; S, segmental glomerulosclerosis; T, tubular atrophy/interstitial fibrosis; and C, cellular/fibrocellular crescents, were used in this study as follows: M0/M1 ($\leq 50\%$ or $> 50\%$ of glomeruli with ≥ 4 mesangial cells/mesangial area), E0/E1 (presence or absence of endocapillary hypercellularity), S0/S1 (presence or absence of segmental glomerulosclerosis), T0/T1/T2 ($\leq 25\%$, 25%-50%, or $> 50\%$ tubular atrophy or interstitial fibrosis), and C0/C1/C2 (absent, $\leq 25\%$, or $> 25\%$ of glomeruli with crescent formation). Glomerular changes were also graded based on the ISKDC classification (Counahan et al. 1977) as follows: grade I, minor glomerular abnormalities; grade II, pure mesangial proliferation (a, focal; b,

diffuse); grade III, minor glomerular abnormalities or mesangial proliferation with crescents in < 50% glomeruli (a, focal; b, diffuse mesangial proliferation); grade IV, same as III but with crescents in 50%-75% of glomeruli (a, focal; b, diffuse mesangial proliferation); grade V, same as III but with crescents in > 75% glomeruli (a, focal; b, diffuse mesangial proliferation); VI, membranoproliferative-like lesions.

Therapeutic protocol

Following the diagnosis of biopsy-proven HSPN, all patients were initially treated with IVMP. Based on the therapeutic protocol for IgAN reported previously (Yamada et al. 2018), the regimen consisted of three courses of IVMP (15-20 mg/kg/day; maximum 600 mg/day) for 3 consecutive days per week for 3 weeks, followed by oral PSL (initially 1 mg/kg; maximum 30 mg) on alternate days. PSL doses were tapered off by dose reductions of 2.5-5 mg every 4-8 weeks depending on the reduction of urinary protein excretion (approximately < 12 months). If proteinuria disappeared rapidly during IVMP treatment, the remaining IVMP course and PSL were discontinued. If the patients continued to have heavy proteinuria after IVMP, treatment with an angiotensin receptor blocker (ARB)/angiotensin converting enzyme inhibitor (ACEI) and/or cyclosporine A (CsA) was initiated. Since 2013, tonsillectomy was additionally performed in all patients within approximately 3 months after initiating IVMP.

To assess treatment outcomes and detect potential steroid toxicities, clinical and laboratory parameters were assessed at baseline, i.e., at the time of renal biopsy, and every 1 month thereafter at our center. The clinical parameters assessed were weight, height, and blood pressure, and laboratory parameters assessed were hematuria and proteinuria (urinalysis) and complete blood counts; immunoglobulin titers; and total protein, albumin, cholesterol, urea, creatinine, electrolyte, and uric acid levels (blood tests).

Statistical analysis

Patient characteristics were summarized using descriptive statistics. Categorical variables were compared using the chi-square or Fisher's exact test as appropriate and are reported as frequencies and percentages. Unless otherwise indicated, continuous variables are expressed as the median (interquartile range; IQR). The parametric two-sample *t* test or non-parametric Mann-Whitney *U* test was used as appropriate for comparison of continuous variables between the two groups. Kaplan-Meier curves of the probability of recurrence-free survival were generated, and the two-sided log-rank test was used for comparison between the two groups. All statistical analyses were performed using STATA version 14.2 (Stata Corp., College Station, TX). In all analyses, $P < 0.05$ was taken to indicate statistical significance.

Results

Table 1 shows the patient characteristics of the two groups at the time of renal biopsy. Median age at the time of renal biopsy was significantly younger in the tonsillectomy group than the IVMP group. Although median eGFR was significantly lower in the tonsillectomy group than the IVMP group, none of the patients had renal insufficiency (eGFR < 60 mL/min/1.73 m²) at the time of renal biopsy. No significant differences were found in the baseline characteristics, such as gender, time to biopsy, rate of hypertension or nephrotic syndrome, UP/C, and histological grade, between the two groups.

Table 2 shows treatment outcomes of the two groups during the study period. Tonsillectomy was performed at a median of 2.4 months (range, 0.5-5.0 months) after IVMP therapy without any significant side effects, such as bleeding and infection requiring additional treatments. After initiating IVMP, proteinuria disappeared in 70 patients (99%) at a median of 3.0 months (tonsillectomy group, 2.7 months; IVMP group, 3.1 months; not significant [N.S.]) and hematuria disappeared in 70 patients (99%) at a median of 8.7 months (tonsillectomy group, 7.4 months; IVMP group, 9.3 months; N.S.). No significant differences were found in the treatment outcomes, such as the rate of disappearance of hematuria or proteinuria, and the duration until disappearance of hematuria or proteinuria, between the two groups. However, the recurrence rate of HSPN after CR was significantly lower in the tonsillectomy group than the IVMP group (0% vs. 25%, respectively, $P < 0.01$). As the follow-up period was significantly longer in the IVMP group than the tonsillectomy group (7.7 vs. 3.4 years, respectively, $P < 0.01$), we compared the recurrence rates of the two groups during the 2-year period after initiating IVMP. However, the recurrence rate of HSPN was still significantly lower in the tonsillectomy group than the IVMP group (0% vs. 19%, respectively, $P < 0.05$). Kaplan-Meier curves also showed that the recurrence rate of HSPN after CR was significantly lower in the tonsillectomy group than the IVMP group (log-rank test, $P < 0.05$) (Fig. 1).

We performed stratification analysis of 40 patients in the IVMP group (Tables 3 and 4). During the follow-up period (median 7.7 years), although all patients achieved CR at a median of 9.3 months after the initiation of IVMP, HSPN recurrence developed in 10 of the 40 patients (25%) at a median of 13.3 months after CR. We compared the characteristics of patients with recurrence ($n = 10$) to those without recurrence ($n = 30$). No significant differences were found in the baseline characteristics, such as gender, age at HSPN onset, time to biopsy, eGFR, and UP/C, between the two groups. Ten of 27 patients with ISKDC grade \geq III developed recurrence, whereas none of the 13 patients with ISKDC grade II showed recurrence during the follow-up period (37% vs. 0%, respectively, $P < 0.01$).

At the last visit, none of the patients had developed renal insufficiency. However, persistent significant protein-

Table 1. Clinical and pathological characteristics of the tonsillectomy group and IVMP group at renal biopsy (baseline).

Patient characteristics	Total (n = 71)	Tonsillectomy group (n = 31)	IVMP group (n = 40)	P value
Age (years)	6.7 (5.9-9.0)	6.4 (5.1-7.5)	7.7 (6.2-10.7)	0.018
Male/female	34/37	17/14	17/23	0.30
Time to biopsy (months)	1.2 (0.8-1.7)	1.2 (0.7-1.9)	1.2 (0.8-1.7)	0.95
Macroscopic hematuria	9 (13%)	5 (16%)	4 (10%)	0.49
Hypertension	1 (1%)	0 (0%)	1 (3%)	1.00
Nephrotic syndrome	11 (15%)	5 (16%)	6 (15%)	0.90
Serum albumin (g/dL)	3.5 (2.9-3.8)	3.6 (2.9-4.1)	3.4 (2.9-3.7)	0.05
eGFR (mL/min/1.73 m ²)	118.6 (102.1-134.3)	109.2 (93.9-122.9)	121.7 (113.0-138.2)	< 0.01
eGFR < 60 mL/min/1.73 m ²	0 (0%)	0 (0%)	0 (0%)	1.00
Morning UP/C (g/g)	2.0 (1.1-5.3)	2.1 (1.0-4.6)	1.9 (1.2-5.3)	0.81
Hematuria (0-6)	4 (3-5)	4 (3-5)	4 (3-5)	0.30
ISKDC Classification				
Grade II	26 (37%)	13(42%)	13 (33%)	0.41
Grade III	44 (62%)	18 (58%)	26 (65%)	0.55
Grade IV	1 (1%)	0 (0%)	1 (3%)	1.00
Oxford Classification				
M0/M1 (%)	80/20	74/26	85/15	0.26
E0/E1 (%)	54/46	48/52	58/43	0.45
S0/S1 (%)	45/55	45/55	45/55	0.99
T0/T1/T2 (%)	100/0/0	100/0/0	100/0/0	1.00
C0/C1/C2 (%)	38/48/14	42/42/16	35/53/13	0.67

Hematuria was quantified based on the red blood cell (RBC) count per high-power field (hpf) on microscopy as 0: < 5/hpf, 1: 5-9/hpf, 2: 10-19/hpf, 3: 20-29/hpf, 4: 30-49/hpf, 5: 50-99/hpf, 6: ≥ 100/hpf.

IVMP, intravenous methylprednisolone pulse.; eGFR, estimated glomerular filtration rate; UP/C, urinary protein-to-creatinine ratio.

uria developed in five of the 10 patients with recurrence in the IVMP group (median UP/C, 0.3 g/g) and received ARB. There were no serious adverse events, such as aseptic femoral necrosis or cataracts, during the follow-up period. There was no significant difference in median standard deviation score for height of the 71 patients at last follow-up in comparison to that at the initiation of the treatment (+0.1SD vs. +0.3SD, respectively, $P = 0.22$).

Discussion

In this study, CR was achieved in most patients within a short period after initiating IVMP, and renal insufficiency did not develop in any of these patients. However, a quarter of the patients in the IVMP group showed recurrence of HSPN after CR and half of the patients with recurrence still had proteinuria at the last visit, whereas all patients in the tonsillectomy group maintained CR without recurrence during the follow-up period. This is the first study to indicate that tonsillectomy may prevent recurrence of HSPN after CR in Japanese children, which could contribute to inhibition of the development of CKD later in life.

Although HSPN is generally regarded as an acute and uniphasic renal disease, previous studies have shown a high rate of CKD development in tertiary centers, particular in patients with persistent proteinuria (Goldstein et al. 1992; Wakaki et al. 2011). In a retrospective study of 42 Japanese

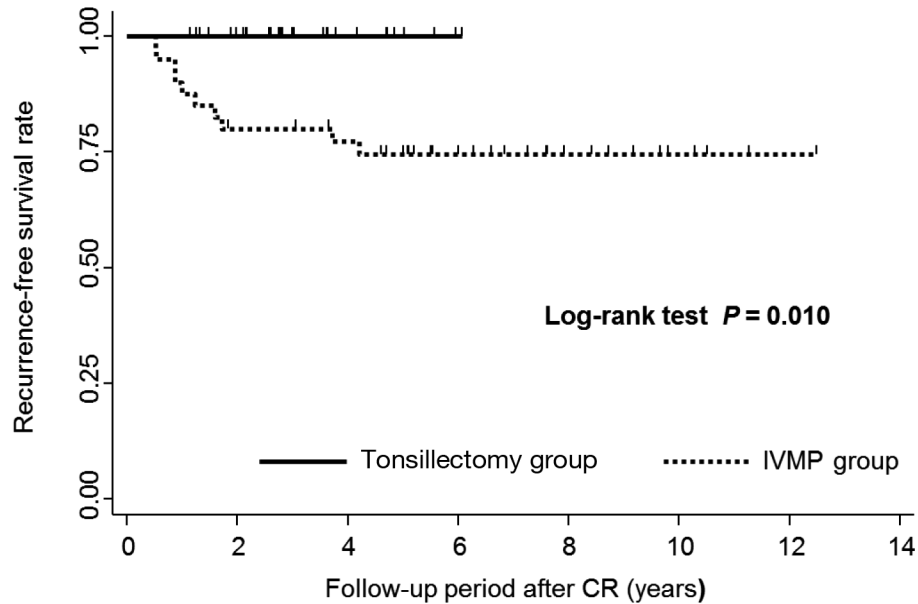
children with HSPN, Wakaki et al. (2011) reported that persistent proteinuria combined with hypoalbuminemia (< 3.0 g/dL) for > 3 months was an independent risk factor for long-term unfavorable renal outcomes (i.e., active renal disease or ESKD). In addition, Goldstein et al. (1992) reported late-developing CKD not only in cases with persistent active renal disease, but also in others achieving CR after the acute phase, probably due to the recurrence of HSPN. The authors also reported that a poor outcome may occur in patients with isolated hematuria or mild proteinuria at onset of HSPN, e.g., the development of CKD observed after repeated episodes of recurrence (Bunchman et al. 1988). In 2012, we reported that early treatment with IVMP was beneficial for achieving CR, but it was not effective for preventing recurrence of HSPN, even in patients with non-nephrotic proteinuria at onset; eight of 23 patients showed reappearance of significant proteinuria combined with hematuria after CR with aggressive treatment (Fujinaga et al. 2012). Since then, we have proposed that tonsillectomy in addition to IVMP should be performed in all HSPN patients with persistent proteinuria in a manner similar to IgAN patients. Surprisingly, as shown in this study, we did not encounter any cases of recurrence of HSPN since the introduction of tonsillectomy in 2013.

Several recent studies in Asian countries have shown that tonsillectomy combined with steroid therapy could

Table 2. Treatment outcomes of the tonsillectomy group and the IVMP group.

	Total (n = 71)	Tonsillectomy group (n = 31)	IVMP group (n = 40)	P value
Follow-up period (years)	5.6 (3.4-8.4)	3.4 (2.7-4.8)	7.7 (5.9-9.9)	< 0.01
Duration of steroid treatment (months)	7.2 (5.9-9.1)	6.7 (5.4-8.8)	8.0 (6.1-9.7)	0.045
Use of CsA	11 (15%)	7 (23%)	4 (10%)	0.13
Use of ARB and/or ACEI	35 (49%)	12 (39%)	23 (58%)	0.12
Disappearance of proteinuria	70 (99%)	30 (97%)	40 (100%)	0.44
Disappearance of hematuria	70 (99%)	30 (97%)	40 (100%)	0.44
Clinical remission (disappearance of hematuria and proteinuria)	69 (97%)	29 (94%)	40 (100%)	0.19
	Total (n = 70)	Tonsillectomy group (n = 30)	IVMP group (n = 40)	P value
Duration until disappearance proteinuria (months)	3.0 (1.6-4.4)	2.7 (1.4-4.2)	3.1 (2.1-4.6)	0.16
Duration until disappearance of hematuria (months)	8.7 (3.8-16.1)	7.4 (0.5-14.4)	9.3 (4.0-20.2)	0.21
	Total (n = 69)	Tonsillectomy group (n = 29)	IVMP group (n = 40)	P value
Duration until clinical remission (months)	8.5 (4.0-15.8)	7.4 (2.7-13.8)	9.3 (4.7-20.2)	0.074
Recurrence after clinical remission	10 (14%)	0 (0%)	10 (25%)	< 0.01
Duration until recurrence after clinical remission (months)	13.3 (10.3-20.6)	-	13.3 (10.3-20.6)	-
	Total (n = 60)	Tonsillectomy group (n = 28)	IVMP group (n = 32)	P value
Recurrence after clinical remission for 2 years after treatment	6 (10%)	0 (0%)	6 (19%)	0.026

IVMP, intravenous methylprednisolone pulse; CsA, cyclosporine A; ACEI, angiotensin converting enzyme inhibitor; ARB, angiotensin receptor blocker.



Tonsillectomy group	29	23	8	1	0	0	0	0
IVMP group	40	31	28	17	9	4	1	0

Fig. 1. Kaplan-Meier curves showing the probability of recurrence-free survival after clinical remission (CR).

The probability of recurrence-free survival in the tonsillectomy group receiving tonsillectomy after IVMP was significantly higher than that in the intravenous methylprednisolone pulse (IVMP) group receiving IVMP monotherapy (log-rank test; $P = 0.010$).

Table 3. Clinical and pathological characteristics of the IVMP group at renal biopsy (baseline).

Patients characteristics	Total (n = 40)	Recurrence (n = 10)	Non-Recurrence (n = 30)	P value
Age (years)	7.7 (6.2-10.7)	6.6 (6.2-9.6)	8.3 (6.3-10.9)	0.60
Male/female	17/23	4/6	13/17	1.00
Time to biopsy (months)	1.2 (0.8-1.7)	1.0 (0.4-1.5)	1.2 (0.8-1.7)	0.43
Macroscopic hematuria	4 (10%)	1 (10%)	3 (10%)	1.00
Hypertension	1 (3%)	1 (10%)	0 (0%)	0.25
Nephrotic syndrome	6 (15%)	1 (10%)	5 (17%)	0.53
Serum albumin (g/dL)	3.4 (2.9-3.7)	3.3 (2.8-3.5)	3.5 (3.1-3.7)	0.32
eGFR (mL/min/1.73 m ²)	121.7 (113.0-138.2)	120.3 (112.3-137.0)	122.5 (113.8-139.5)	0.60
eGFR < 60 mL/min/1.73 m ²	0 (0%)	0 (0%)	0 (0%)	1.00
Morning UP/C (g/g)	1.9 (1.2-5.3)	1.7 (0.9-3.5)	2.0 (1.5-5.3)	0.49
Hematuria (0-6)	4 (3-5)	4 (3-5)	5 (3-6)	0.21
ISKDC Classification				
Grade II	13 (33%)	0 (0%)	13 (43%)	0.016
Grade III	26 (65%)	9 (90%)	17 (57%)	0.06
Grade IV	1 (3%)	1 (10%)	0 (0%)	0.25
Oxford Classification				
M0/M1 (%)	85/15	70/30	90/10	0.15
E0/E1 (%)	58/43	50/50	60/40	0.58
S0/S1 (%)	45/55	40/60	47/53	1.00
T0/T1/T2 (%)	100/0/0	100/0/0	100/0/0	1.00
C0/C1/C2 (%)	35/53/13	10/70/20	43/47/10	0.11

Hematuria was quantified based on the red blood cell (RBC) count per high-power field (hpf) on microscopy as 0: < 5/hpf, 1: 5-9/hpf, 2: 10-19/hpf, 3: 20-29/hpf, 4: 30-49/hpf, 5: 50-99/hpf, 6: ≥ 100/hpf.
IVMP, intravenous methylprednisolone pulse; eGFR, estimated glomerular filtration rate; UP/C, urinary protein-to-creatinine ratio.

Table 4. Treatment outcomes of the IVMP group.

	Total (n = 40)	Recurrence (n = 10)	Non-Recurrence (n = 30)	P value
Follow-up period (years)	7.7 (5.9-9.9)	10.0 (8.4-12.5)	6.6 (5.4-8.8)	< 0.01
Duration of steroid treatment (months)	8.0 (6.1-9.7)	8.3 (6.1-12.3)	8.0 (6.0-9.1)	0.45
Use of CsA	4 (10%)	1 (10%)	3 (10%)	0.74
Use of ARB and/or ACEI	23 (58%)	7 (70%)	16 (53%)	0.29
Disappearance of proteinuria	40 (100%)	10 (100%)	30 (100%)	1.00
Disappearance of hematuria	40 (100%)	10 (100%)	30 (100%)	1.00
Clinical remission	40 (100%)	10 (100%)	30 (100%)	1.00
Duration until disappearance of proteinuria (months)	3.1 (2.1-4.6)	4.0 (3.0-4.9)	3.0 (1.9-4.1)	0.24
Duration until disappearance of hematuria (months)	9.3 (4.0-20.2)	10.1 (0.3-17.2)	9.1 (4.1-20.7)	0.78
Duration until clinical remission (months)	9.3 (4.7-20.2)	10.1 (4.6-17.2)	9.1 (5.0-20.7)	1.00
Duration until recurrence after clinical remission (months)	13.3 (10.3-20.6)	13.3 (10.3-20.6)	-	-
	Total (n = 32)	Recurrence (n = 9)	Non-Recurrence (n = 23)	P value
Recurrence until clinical remission for 2 years after treatment	6 (19%)	6 (67%)	0 (0%)	< 0.01

IVMP, intravenous methylprednisolone pulse; CsA, cyclosporine A; ACEI, angiotensin converting enzyme inhibitor; ARB, angiotensin receptor blocker.

reduce the incidence of recurrence after CR in adult patients with IgAN (Ohya et al. 2013; Hirano et al. 2016; Yang et al. 2016), whereas this was not supported by the data collected from a European (VALIGA) cohort; Feehally et al. (2016)

reported that IgA nephropathy developed later in 44 Caucasian patients who had undergone tonsillectomy during childhood because of recurrent episodes of tonsillitis and obstructive sleep apnea. Ohya et al. (2013) retrospec-

tively investigated the recurrence rate after CR in Japanese adult patients with IgAN undergoing tonsillectomy combined with IVMP ($n = 41$) and compared their outcomes with those of patients receiving IVMP monotherapy ($n = 21$). In their study, Kaplan–Meier analysis demonstrated that tonsillectomy was significantly associated with a lower rate of IgAN recurrence from CR after IVMP (log-rank test, $P = 0.045$), which was consistent with the results of our study in childhood HSPN. Furthermore, they found that recurrence occurred with almost the same timing in patients with IVMP monotherapy (between 10 and 20 months), which was also similar to the results of the IVMP group in our study (median 13.3 months, IQR 10.3–20.6 months). In a recent RCT of Chinese adult patients with IgAN, Yang et al. (2016) reported that tonsillectomy combined with drug therapy was more effective than drug therapy alone in both achieving remission and preventing recurrence. They concluded that tonsillectomy can contribute to the preservation of kidney function in IgAN patients. In a more recent retrospective study of Japanese adult patients with IgAN, Hirano et al. (2016) reported that tonsillectomy was significantly associated with a lower rate of recurrence after CR following IVMP, particularly in patients with mesangial hypercellularity (log-rank test, $P = 0.022$). In addition, they found that a high score of Japanese histological grade (i.e., $\geq 25\%$ of glomeruli exhibiting crescents and/or sclerosis) was an independent risk factor for the development of recurrence after CR ($P = 0.008$). In our study, none of the patients with ISKDC grade II (no crescents) developed recurrence during the follow-up period, regardless of whether tonsillectomy was performed. Furthermore, although not significant, the percentages of M0 (no mesangial hypercellularity) and C0 (no crescents) by the new Oxford Classification were higher in the non-recurrence group than the recurrence group (Haas et al. 2017; Trimarchi et al. 2017). Based on these results, histological findings before treatment may predict not only the response to tonsillectomy, but also the risk of disease recurrence in Japanese patients; tonsillectomy may be not necessarily suitable for childhood HSPN without crescent formation.

In contrast to previous studies in adult patients with IgAN, there have been no reports regarding the impact of tonsillectomy for prevention of HSPN recurrence in children. Kawasaki et al. (2007) first described the efficacy of tonsillectomy in an 11-year-old boy with HSPN who had persistent active renal disease accompanied by recurrent HSP with tonsillitis despite conventional immunosuppressive therapy. After tonsillectomy, neither proteinuria nor macroscopic hematuria accompanied by purpura was noted during the 36-month follow-up in their patient. The authors concluded that chronic tonsillitis may play an important role in the pathogenesis of HSPN. In addition, Inoue et al. (2007) reported that tonsillectomy combined with IVMP at an early stage in cases of childhood HSPN may be effective in achieving CR. None of their patients had a history of recurrent tonsillitis in contrast to the patient reported by

Kawasaki et al. (2007). They reported no recurrence of purpura in 16 patients over a mean follow-up period of 4.9 years, including two patients who had experienced recurrence before tonsillectomy. Interestingly, Kamei et al. (2016) reported the late development of purpura in six of 53 children with primary IgAN (11%) who did not undergo tonsillectomy at a median of 5.5 years after onset of the disease. Although we agree with their speculation that IgAN and HSPN are variants of a single disease, purpura did not develop in 54 children with primary IgAN undergoing tonsillectomy at our hospital during the follow-up period (median 5.0 years) (Yamada et al. 2018). Therefore, we speculate that tonsillectomy may play an essential role in the prevention of not only recurrence of proteinuria but also purpura development in Japanese children with primary IgAN.

Although the pathogenesis of IgAN and HSPN remain to be elucidated, it has been speculated that oversecretion of galactose-deficient IgA1 (Gd-IgA1) after antigenic stimulation may result in the deposition of IgA1 in glomeruli and renal deterioration (Suzuki and Tomino 2008). The frequent association of tonsillitis with episodes of macroscopic hematuria in patients with IgAN and HSPN has led to the hypothesis that Gd-IgA1 may be produced in the tonsils. Although the normal human tonsils contain 60% IgG-producing plasma cells and 40% IgA-producing plasma cells, Béné et al. (1991) reported that both the percentage and number of IgA-producing plasma cells were significantly increased in tonsils of patients with IgA nephropathy. In fact, Horie et al. (2003) reported that tonsils produced Gd-IgA1 molecules in four patients with IgA nephropathy. Unfortunately, we did not perform histopathological analysis in the tonsil tissues of our patients. Nakata et al. (2014) reported that serum Gd-IgA1 levels in IgAN patients decreased by 59% after tonsillectomy alone, indicating that the tonsils are one of the major sites of Gd-IgA1-producing cells. We postulated that tonsillectomy may be beneficial in preventing recurrence by eliminating the repeated antigenic stimulation from the tonsillar mucosa. Histologically, enlarged follicular areas of tonsils, where antigen-specific T cell activation and subsequent T cell-B cell interaction take place, are considered to be characteristic of IgAN (Kawaguchi et al. 1993). In the tonsil tissues of IgAN patients, Adachi et al. (2018) recently reported that the proportion of the follicular area became very small immediately after IVMP therapy. Although these histological findings lasted for approximately 3 months after IVMP therapy, the tonsil tissue structure was gradually restored with a gradual decrease of oral PSL, which may explain the mechanism of recurrence in IgAN and HSPN patients with IVMP monotherapy. Furthermore, the lack of recurrence in our patients in the tonsillectomy group may be explained by the timing of tonsillectomy (i.e., < 3 months after IVMP therapy).

Our study had some limitations. First, it was a single-center retrospective study with a small number of patients.

To the best of our knowledge, however, the number of children with HSPN undergoing tonsillectomy combined with IVMP in this study was the largest reported to date in the literature. Furthermore, this is the first study on recurrence-free survival in children with HSPN to compare tonsillectomy after IVMP therapy with IVMP monotherapy. Second, the follow-up period was relatively short, especially in patients undergoing tonsillectomy after IVMP therapy. Therefore, we could not evaluate the long-term prognosis of children with HSPN after tonsillectomy. However, we speculated that renal outcome of these patients may be favorable because none had significant proteinuria on the last visit. Third, as all patients in this study were Japanese, the results regarding the positive effects of tonsillectomy cannot be generalized to cohorts of different ethnicities, such as Caucasian patients. Finally, historical control data were used to assess the impact of tonsillectomy; thus, there seems to be a selection bias between tonsillectomy group and IVMP group. Mean age at renal biopsy was significantly older in the IVMP group than the tonsillectomy group. Older patients seem to be closer to patients with IgA nephropathy and this may explain the poor prognosis of the IVMP group. Therefore, further multicenter, prospective randomized controlled studies are required to accurately determine the impact of tonsillectomy after IVMP therapy for preventing recurrence of childhood HSPN.

In conclusion, the results of the present study indicated that initial treatment with IVMP followed by oral PSL appears to be effective for achieving CR in cases of childhood HSPN, regardless of whether tonsillectomy is also performed. However, a quarter of the patients that did not undergo tonsillectomy showed HSPN recurrence and half of the patients with recurrence had persistent proteinuria, indicating risk of developing CKD in this cohort. Although the follow-up period in the tonsillectomy group was relatively short (median 3.4 years), tonsillectomy may prevent recurrence after IVMP therapy in Japanese children with HSPN.

Acknowledgments

The authors wish to thank Dr. Hitohiko Murakami (Division of Pathology, Saitama Children's Medical Center) for his excellent contributions.

S.F. has received clinical research funding B at Saitama Children's Medical Center.

Conflict of Interest

The authors declare no conflict of interest.

References

Adachi, M., Sato, M., Miyazaki, M., Hotta, O., Hozawa, K., Sato, T., Taguma, Y. & Katori, Y. (2018) Steroid pulse therapy transiently destroys the discriminative histological structure of tonsils in IgA nephropathy: tonsillectomy should be performed before or just after steroid pulse therapy. *Auris Nasus Larynx*,

45, 1206-1213.

- Béné, M.C., Hurault De Ligny, B., Kessler, M. & Faure, G.C. (1991) Confirmation of tonsillar anomalies in IgA nephropathy: a multicenter study. *Nephron*, **58**, 425-428.
- Bunchman, T.E., Mauer, S.M., Sibley, R.K. & Vernier, R.L. (1988) Anaphylactoid purpura: characteristics of 16 patients who progressed to renal failure. *Pediatr. Nephrol.*, **2**, 393-397.
- Counahan, R., Winterborn, M.H., White, R.H., Heaton, J.M., Meadow, S.R., Bluett, N.H., Swetschin, H., Cameron, J.S. & Chantler, C. (1977) Prognosis of Henoch-Schonlein nephritis in children. *Br. Med. J.*, **2**, 11-14.
- Davin, J.C. & Coppo, R. (2014) Henoch-Schonlein purpura nephritis in children. *Nat. Rev. Nephrol.*, **10**, 563-573.
- Feehally, J., Coppo, R., Troyanov, S., Bellur, S.S., Cattran, D., Cook, T., Roberts, I.S., Verhave, J.C., Camilla, R., Vergano, L., Egido, J., Wiecek, A., Karkoszka, H., Tesar, V., Maixnerova, D., et al. (2016) Tonsillectomy in a European cohort of 1,147 patients with IgA nephropathy. *Nephron*, **132**, 15-24.
- Fujinaga, S., Endo, A. & Hirano, D. (2012) Outcome of children with heavy non-nephrotic proteinuria in Henoch-Schonlein nephritis. *Pediatr. Nephrol.*, **27**, 331-332; author reply 333-334.
- Fujinaga, S., Ohtomo, Y., Murakami, H., Takemoto, M., Yamashiro, Y. & Kaneko, K. (2006) Recurrence of Henoch-Schonlein purpura nephritis after long-term remission in a 15-year-old girl. *Pediatr. Nephrol.*, **21**, 1215-1216.
- Goldstein, A.R., White, R.H., Akuse, R. & Chantler, C. (1992) Long-term follow-up of childhood Henoch-Schonlein nephritis. *Lancet*, **339**, 280-282.
- Haas, M., Verhave, J.C., Liu, Z.H., Alpers, C.E., Barratt, J., Becker, J.U., Cattran, D., Cook, H.T., Coppo, R., Feehally, J., Pani, A., Perkowska-Ptasinska, A., Roberts, I.S., Soares, M.F., Trimarchi, H., et al. (2017) A multicenter study of the predictive value of crescents in IgA nephropathy. *J. Am. Soc. Nephrol.*, **28**, 691-701.
- Hirano, K., Amano, H., Kawamura, T., Watanabe, K., Koike, K., Shimizu, A., Endo, S., Tsuboi, N., Okonogi, H., Miyazaki, Y., Ikeda, M., Hanaoka, K., Ogura, M., Komatsumoto, S. & Yokoo, T. (2016) Tonsillectomy reduces recurrence of IgA nephropathy in mesangial hypercellularity type categorized by the Oxford classification. *Clin. Exp. Nephrol.*, **20**, 425-432.
- Horie, A., Hiki, Y., Odani, H., Yasuda, Y., Takahashi, M., Kato, M., Iwase, H., Kobayashi, Y., Nakashima, I. & Maeda, K. (2003) IgA1 molecules produced by tonsillar lymphocytes are under-O-glycosylated in IgA nephropathy. *Am. J. Kidney Dis.*, **42**, 486-496.
- Hotta, O., Miyazaki, M., Furuta, T., Tomioka, S., Chiba, S., Horigome, I., Abe, K. & Taguma, Y. (2001) Tonsillectomy and steroid pulse therapy significantly impact on clinical remission in patients with IgA nephropathy. *Am. J. Kidney Dis.*, **38**, 736-743.
- Ieiri, N., Hotta, O., Sato, T. & Taguma, Y. (2012) Significance of the duration of nephropathy for achieving clinical remission in patients with IgA nephropathy treated by tonsillectomy and steroid pulse therapy. *Clin. Exp. Nephrol.*, **16**, 122-129.
- Inoue, C.N., Chiba, Y., Morimoto, T., Nishio, T., Kondo, Y., Adachi, M. & Matsutani, S. (2007) Tonsillectomy in the treatment of pediatric Henoch-Schonlein nephritis. *Clin. Nephrol.*, **67**, 298-305.
- Kamei, K., Ogura, M., Sato, M., Ito, S. & Ishikura, K. (2016) Evolution of IgA nephropathy into anaphylactoid purpura in six cases: further evidence that IgA nephropathy and Henoch-Schonlein purpura nephritis share common pathogenesis. *Pediatr. Nephrol.*, **31**, 779-785.
- Kanai, H., Sawanobori, E., Kobayashi, A., Matsushita, K., Sugita, K. & Higashida, K. (2011) Early treatment with methylprednisolone pulse therapy combined with tonsillectomy for heavy proteinuric henoch-schonlein purpura nephritis in children. *Nephron Extra*, **1**, 101-111.

- Kawaguchi, M., Sakai, T., Sakamaki, A., Ishizawa, S., Baba, Y., Masuda, Y. & Koizumi, F. (1993) Expanded primary T nodules in the palatine tonsils from patients with IgA nephropathy. *Acta Otolaryngol. Suppl.*, **508**, 36-42.
- Kawamura, T., Yoshimura, M., Miyazaki, Y., Okamoto, H., Kimura, K., Hirano, K., Matsushima, M., Utsunomiya, Y., Ogura, M., Yokoo, T., Okonogi, H., Ishii, T., Hamaguchi, A., Ueda, H., Furusu, A., et al. (2014) A multicenter randomized controlled trial of tonsillectomy combined with steroid pulse therapy in patients with immunoglobulin A nephropathy. *Nephrol. Dial. Transplant.*, **29**, 1546-1553.
- Kawasaki, Y., Suyama, K., Matsumoto, A., Takano, K., Hashimoto, K., Suzuki, S., Suzuki, J., Suzuki, H. & Hosoya, M. (2007) Efficacy of tonsillectomy plus methylprednisolone pulse therapy for a child with Henoch-Schoenlein purpura nephritis. *Tohoku J. Exp. Med.*, **211**, 291-295.
- Nakata, J., Suzuki, Y., Suzuki, H., Sato, D., Kano, T., Yanagawa, H., Matsuzaki, K., Horikoshi, S., Novak, J. & Tomino, Y. (2014) Changes in nephritogenic serum galactose-deficient IgA1 in IgA nephropathy following tonsillectomy and steroid therapy. *PLoS One*, **9**, e89707.
- National High Blood Pressure Education Program Working Group on High Blood Pressure in Children and Adolescents (2004) The fourth report on the diagnosis, evaluation, and treatment of high blood pressure in children and adolescents. *Pediatrics*, **114**, 555-576.
- Niaudet, P. & Habib, R. (1998) Methylprednisolone pulse therapy in the treatment of severe forms of Schonlein-Henoch purpura nephritis. *Pediatr. Nephrol.*, **12**, 238-243.
- Ohya, M., Otani, H., Minami, Y., Yamanaka, S., Mima, T., Negi, S., Yukawa, S. & Shigematsu, T. (2013) Tonsillectomy with steroid pulse therapy has more effect on the relapse rate than steroid pulse monotherapy in IgA nephropathy patients. *Clin. Nephrol.*, **80**, 47-52.
- Rai, A., Nast, C. & Adler, S. (1999) Henoch-Schonlein purpura nephritis. *J. Am. Soc. Nephrol.*, **10**, 2637-2644.
- Suzuki, Y. & Tomino, Y. (2008) Potential immunopathogenic role of the mucosa-bone marrow axis in IgA nephropathy: insights from animal models. *Semin. Nephrol.*, **28**, 66-77.
- Trimarchi, H., Barratt, J., Cattran, D.C., Cook, H.T., Coppo, R., Haas, M., Liu, Z.H., Roberts, I.S., Yuzawa, Y., Zhang, H. & Feehally, J.; IgAN Classification Working Group of the International IgA Nephropathy Network and the Renal Pathology Society; Conference Participants (2017) Oxford Classification of IgA nephropathy 2016: an update from the IgA Nephropathy Classification Working Group. *Kidney Int.*, **91**, 1014-1021.
- Uemura, O., Nagai, T., Ishikura, K., Ito, S., Hataya, H., Gotoh, Y., Fujita, N., Akioka, Y., Kaneko, T. & Honda, M. (2014) Creatinine-based equation to estimate the glomerular filtration rate in Japanese children and adolescents with chronic kidney disease. *Clin. Exp. Nephrol.*, **18**, 626-633.
- Wakaki, H., Ishikura, K., Hataya, H., Hamasaki, Y., Sakai, T., Yata, N., Kaneko, T. & Honda, M. (2011) Henoch-Schonlein purpura nephritis with nephrotic state in children: predictors of poor outcomes. *Pediatr. Nephrol.*, **26**, 921-925.
- Yamada, A., Fujinaga, S., Sakuraya, K., Satoshi, A. & Hirano, D. (2018) Initial treatment with pulse methylprednisolone followed by short-term prednisolone and tonsillectomy for childhood IgA nephropathy. *Clin. Exp. Nephrol.*, **22**, 1143-1149.
- Yang, D., He, L., Peng, X., Liu, H., Peng, Y., Yuan, S., Liu, Y., Chen, X., Liu, F. & Liu, C. (2016) The efficacy of tonsillectomy on clinical remission and relapse in patients with IgA nephropathy: a randomized controlled trial. *Ren. Fail.*, **38**, 242-248.